

Study of lip print pattern in a Punjabi population

Simarpreet Virk Sandhu,
Himanta Bansal,
Poonam Monga,
Rajat Bhandari

Department of Oral and
Maxillofacial Pathology,
Genesis Institute of Dental
Sciences and Research,
Ferozepur, Punjab, India

Address for correspondence:

Dr. Simarpreet Virk Sandhu,
Professor and Head, Department
of Oral and Maxillofacial
Pathology, Genesis Institute of
Dental Sciences and Research,
Ferozepur Moga Road,
Ferozepur - 152001, Punjab, India.
E-mail: s_vrk@yahoo.com

Abstract

Background: Lip prints are unique to each individual and can be used for personal identification. The lip prints show differences according to the race and the ethnic origins of a person. **Aim:** The objective of the study was to determine the predominant lip print type in a Punjabi population. **Materials and Methods:** The study was conducted on 106 students of our institution and comprised 56 males and 50 females in the age group of 18-25 years. The middle part of the lower lip was taken as study area. Analysis of lip print pattern was done according to Tsuchihashi Classification. **Results:** No two lip prints matched with each other. Type 1 pattern (vertical grooves that run across the entire lip) was found to be predominant in both males (51.02%) and females (43.47%) and there was no statistically observed difference between males and females in individual lip print types. **Conclusion:** In our study, lip prints did not match with each other, hence lip prints are unique and further studies with larger samples are required to obtain statistical significance.

Key words: Cheiloscopy, evidence, forensic odontology, lip prints, personal identification, Punjabi population

Introduction

Human identification is a universal process based on scientific principles.^[1] Traditional methods of personal identification include anthropometry, dactyloscopy, DNA fingerprinting, postmortem records and differentiation by blood groups.^[2] The theory of uniqueness is a strong point used in the analysis of fingerprints; likewise the lip print of an individual is unique and hence holds potential for personal identification. Lip prints are usually left at the crime scene and provide a direct link to the suspect. Wrinkles and grooves present on the labial mucosa called as "Sulci Labiorum" form a characteristic pattern called "Lip Prints" the study of which is known as Cheiloscopy.^[3]

Historical prospective

Fischer, in 1902, was the first anthropologist to describe the furrows on the red part of human lips.^[4] Use of lip prints was first recommended as early as in 1932 by Edmond Locard.^[1] In 1961 the first study on the lip print was carried out in Hungary. In Poland interest in the lip print pattern started when a pattern was revealed on a window glass at the scene of a burglary in 1966. Two Japanese scientists, Y. Tsuchihashi and T. Suzuki in the period 1968-71, established that the arrangement of lines on the red part of the human lip is individual and unique for each human being.^[5] They named the grooves as Sulci Labiorum and lip prints consisting of these grooves as "Figura Linearum Labiorum Rubrorum". Cottone in 1981 reported that cheiloscopy is one of the special techniques used for the purpose of identification.^[4] In 1985-87, cheiloscopy techniques were used in 85 cases including 65 cases of burglary, 15 cases of homicide and five cases of assault. In 34 cases, the identification was positive which means that the cheiloscopic techniques were equal in value with other types of forensic sciences.^[5] In 1967 Santos was the first person to classify lip grooves. He divided them into four types, namely, Straight line; Curved line; Angled line and Sine-shaped curve.^[4]

Access this article online

Website:
www.jfds.org

DOI:
10.4103/0975-1475.99157

Quick Response Code



Lip prints may also be used in detection, being a source of criminalistic information. A lip print at the scene of the crime can be a clue to the character of the event, the number, sex, habits and occupation of people involved. It also provides information about the cosmetics used and the pathological changes of lips themselves. Practical use of lip prints in detection work shows that traces of this kind carry a huge amount of precious information which can be used in the reconstruction of an event and identifying suspects. Previous studies reveal that lip prints show differences according to the race and the ethnic origins of a person. The present study was undertaken to determine the predominant lip pattern type in a Punjabi population of the Indian subcontinent.

Materials and Methods

Study sample

The study was conducted on 106 students of our institution and comprised 56 males and 50 females. The subjects were aged between 18 to 25 years and were of Punjabi origin (natives of Punjab and born in Punjab to Punjabi parents). All the participants were briefed about the purpose of the study and a written consent was obtained from each of them. Exclusion Criteria: Patients undergoing orthodontic treatment, or with presence of congenital abnormalities, inflammation or trauma were excluded. Subjects with known hypersensitivity to lipsticks were not included.

Study materials

Red-colored lipstick, lip brush, cellophane tape, white bond paper, and a magnifying glass.

Technique

The lips of the individuals were cleaned and a red-colored lipstick was applied evenly with a single stroke on the vermilion border and subjects were asked to rub both the lips and spread the applied lipstick [Figures 1 and 2]. After about 2 min, the glued portion of the cellophane tape was placed over the lipstick [Figure 3]. Lip prints were obtained in the normal rest position by dabbing in the centre first and then pressing it comfortably towards the corner of the lips. The cellophane strip was then stuck to the white bond paper for a permanent record and then visualized through a magnifying glass [Figures 4 and 5]. The number of lines and furrows present on the middle part of the lower lip, their length, branching and combination were noted as proposed by Sivapathasundaram *et al.*

In this study, the classification of the patterns of the lines on the lip as proposed by Tsuchihashi was followed^[6] [Figure 6]:
 Type I: Clear-cut vertical grooves that run across the entire lip [Figure 7].

Type I': Similar to Type I but does not cover the entire lip. [Figure 8].

Type II: Branched grooves (Y-shaped pattern) [Figure 9]

Type III: Intersecting [Figure 10]

Type IV: Crisscross patterns, reticular grooves [Figure 11]

Type V: Undetermined [Figure 12]

The data was compiled and analyzed by z-test and *P* value less than 0.05 was considered significant.

Results

A total of 106 subjects were included in the study, comprising 56 males and 50 females, in the age group of 18-25 years. In

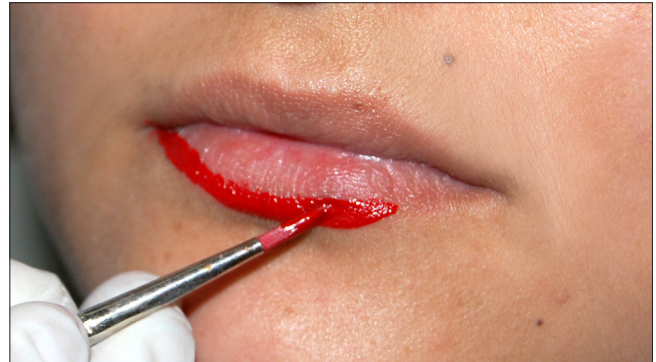

Figure 1: Application of lipstick



Figure 2: Rolling of lips to spread the lipstick

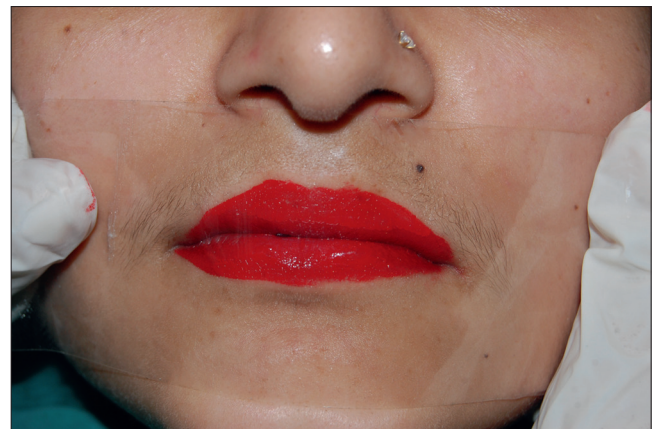

Figure 3: Impression being taken on the glued surface of the cellophane tape



Figure 4: Sticking the cellophane tape on bond paper



Figure 5: Lip print pattern of a full lip

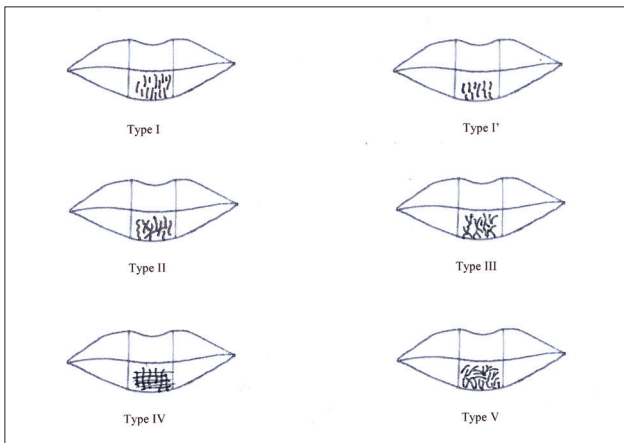


Figure 6: Various lip print patterns



Figure 7: Type I: Clear-cut vertical grooves that run across the entire lip

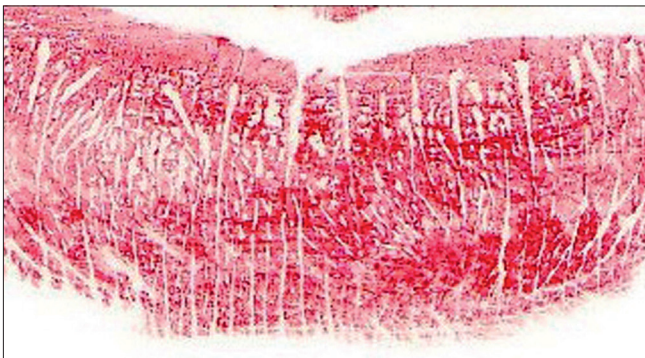


Figure 8: Type I': Similar to Type I but does not cover the entire lip

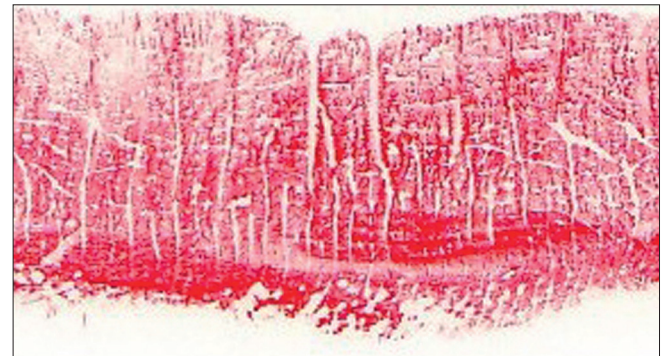


Figure 9: Type II: Branched grooves (Y-shaped pattern)

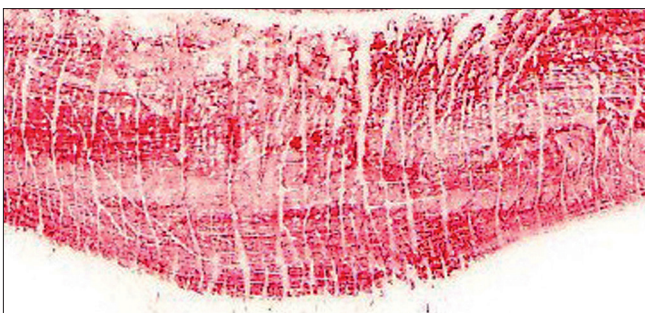


Figure 10: Type III: Intersecting

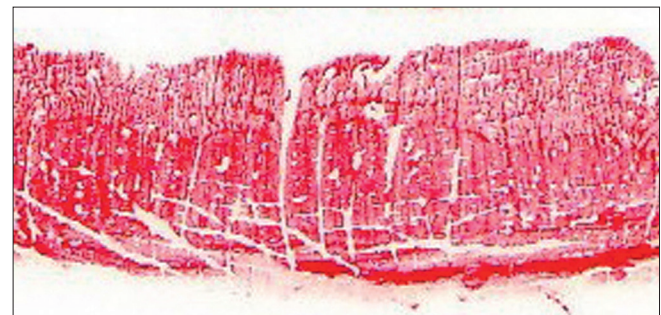


Figure 11: Type IV: Crisscross patterns, reticular grooves

our study no two lip print patterns matched each other thus establishing the uniqueness of lip prints.

In our study it was found that Type I (clear-cut vertical

grooves that run across the entire lip) was the predominant pattern in both males and females, 44.64% and 40% respectively. This was followed by Type II (branched grooves), 21.43% in males and 22% in females. In females we did not find even a single case of Type V (undetermined) pattern and in males Type IV (crisscross patterns, reticular grooves) was the least common of all patterns [Chart 1].

There is no statistically observed difference between males and females in individual lip print types [Table 1].

A few of the lip prints which were of poor quality were discarded—12.5% in males and 8% in females were not included in the study.

Discussion

Cheiloscopy is an upcoming tool for the identification of a person’s lip print. It is one of the most interesting and emerging methods of human identification, and originates from criminal and forensic practice.^[5] Lip




Figure 12: Type V: Undetermined

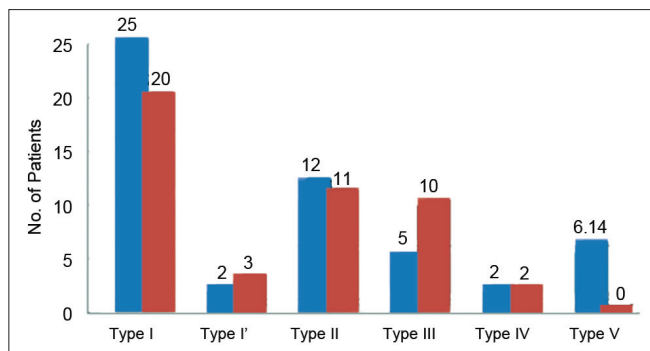


Chart 1: Common lip print patterns in males and females

Table 1: Lip print patterns in males and females

Type	Female		Male		P value
	No.	% age	No.	% age	
Type I	20	40.00	25	44.64	0.34177
Type I'	3	6.00	2	3.57	0.28025
Type II	11	22.00	12	21.43	0.91557
Type III	10	20.00	5	8.93	0.10107
Type IV	2	4.00	2	3.57	0.82744
Type V	0	0.00	3	5.36	0.09938
Discarded	4	8.00	7	12.50	0.21757

prints are unique and do not change during the life of a person.^[2] These can be obtained at the crime scene from clothing, cups, cigarettes, windows and doors.^[5] Use of lipstick is not inevitable as latent prints are available at all crime scenes because of the presence of minor salivary glands and sebaceous glands. The secretions along with continual moisturizing by the tongue leads to latent lip print formation which can be obtained on items such as glass and can be obtained up to 30 days after being produced.^[4]

The current study was conducted using the classification system adopted from the study of Tsuchihashi *et al.*, who in spite of the limited studies done in the field have proposed a standard classification of their own for different types of lip prints.^[6]

The middle portion of the lip (10-mm wide) was taken as the study area for classification as proposed by Sivapathasundaram *et al.* This area is almost always visible in any trace and the determination of the pattern depends on the numerical superiority of the lines on this study area.^[3]

In our study no two lip print patterns matched each other thus establishing the uniqueness of lip prints. Tsuchihashi *et al.*, also reported such combinations in their investigations on 1364 subjects. They also asserted that no two lip prints were exactly identical, not even on the 49 pairs of uniovular twins studied as a part of their study.

In our study it was found that Type I (clear-cut vertical grooves that run across the entire lip) was the predominant pattern in both males and females, 44.64% and 40% respectively. This was followed by Type II (branched grooves), 21.43% in males and 22% in females. In females we did not find even a single case of Type V (undetermined) pattern and in males Type IV (crisscross patterns, reticular grooves) was the least common of all patterns.

In our study 10.3% of all lip prints were spoilt, maximum being in males (7/11) which could be attributed to the presence of prominent facial hair among men. Lip print recording is technique-sensitive and can be altered due to any debris on the lip surface, application of a thick layer of lipstick and overstretching of cellophane tape.^[7,8]

Various studies in India have shown population-wise dominance. Sivapathasundaram *et al.*, and Saraswati *et al.*, studied lip print patterns and found that Type III was the predominant lip pattern in the Indo-Dravidian population.^[3,4] Varghese *et al.*, found Type IV as a predominant pattern in both males and females in subjects from Kerala.^[9] In our study we found that the vertical pattern (Type I) was the most common lip print pattern in both the sexes in the Punjabi population [Table 2].

Table 2: Study of lip print patterns in different population types

Reference	Region	Predominant lip pattern
Sivapathasundaram <i>et al.</i> ^[3]	Tamilnadu	Type III in both males and females
Manipady ^[9]	Karnataka	Type II in both males and females
Gondivkar MS <i>et al.</i> ^[2]	Maharashtra	Entire study population :Type II Males : Type III Females: Type II
Sharma P <i>et al.</i> ^[11]	Uttar Pradesh	Type I, I' commonly seen in females Type IV commonly seen in males
Saraswathi TR <i>et al.</i> ^[4]	Tamilnadu	Type III (Intersecting pattern) was common among both males and females
Vahanwala <i>et al.</i> ^[10]	Maharashtra	Female: Type II Males: Type III
Vergheese AJ <i>et al.</i> ^[9]	Kerala	Type IV (reticular) pattern predominant in both males and females
Our study	Punjab	Type I (vertical) is the predominant type in both males (44.64%) & females (40%).

Godivkar *et al.*, in 2009 studied male and female subjects in Maharashtra and were able to predict sex with high degree of accuracy.^[2] The results of our study do not coincide with the above observations. We did not observe any statistically significant difference between males and females in individual lip print types in our study group. Our results are in accordance with Sivapathasundaram *et al.*, Saraswathi *et al.* and Vargheese *et al.*^[3,4,9]

India is a vast country with large ethnic variation. More studies should be conducted in different centers with a larger sample size to form a Cohesive Cheiloscopy System which would be a useful tool in forensic odontology. There are certain limitations. Various factors can alter lip print recording. Postmortem alterations of the lip can lead to erroneous data if the lip prints are not obtained within 24 hrs of death. The patterns also depend on the position of the lip. The closed mouth position lips exhibit well-defined grooves and are easy to interpret which is not the case with the open position lips. There can be erroneous results in case of pathology and loss of front teeth. The lip print appearance may also be affected by the pressure, direction and method used while taking the impression.^[7,10]

Conclusion

Lip prints are unique for every person and show differences according to the race and the ethnic origins of a person.^[9] In our study no two lip print patterns matched each other thus establishing the uniqueness of lip prints. It was found that Type I (clear-cut vertical grooves that run across the entire lip) was the predominant pattern in both males and females. We did not observe any statistically significant difference between males and females in individual lip print types. Though emerging as a promising tool, lip print recording is a tedious task which is technique-sensitive. More collaborative work needs to be done involving multiple centers and larger study groups to reach a consensus in order to have practical implications.

References

1. Sharma P, Saxena S, Rathod V. Cheiloscopy: The study of lip prints in sex identification. *J Forensic Dent Sci* 2009;1:24-7.
2. Gondivkar MS, Indurkar A, Degwekar S, Bhowate R. Cheiloscopy for sex determination. *J Forensic Dent Sci* 2009;1:56-9.
3. Sivapathasundaram B, Prakash PA, Sivakumar G. Lip prints (Cheiloscopy). *Indian J Dent Res* 2001;12:234-7.
4. Saraswathi TR, Misra G, Ranganathan K. Study of lip prints. *J Forensic Dent Sci* 2009;1:28-31.
5. Reddy LV. Lip prints: An overview in forensic dentistry. *J Adv Dent Res* 2011;11:16-20.
6. Shafer, Hine, Levy. *Shafer's textbook of Oral Pathology* 2009. 6th ed. ch. 21: p. 896.
7. Kavitha B, Einstein A, Sivapathasundaram B, Saraswathi TR. Limitations in forensic odontology. *J Forensic Dent Sci* 2009;1:8-10.
8. Ball J. The current status of lip prints and their use for identification. *J Forensic Odontostomatol* 2002;20:43-6.
9. Vergheese AJ, Somasekar M, Umesh BR. A study on lip print types among the people of Kerala. *J Indian Acad Forensic Med* 2010; 32:6-7.
10. Vahanwalla SP, Parekh BK. Study on lip prints as an aid to forensic methodology. *J Forensic Med Toxicol* 2000;17:12-8.

How to cite this article: Sandhu SV, Bansal H, Monga P, Bhandari R. Study of lip print pattern in a Punjabi population. *J Forensic Dent Sci* 2012;4:24-8.

Source of Support: Nil, **Conflict of Interest:** None declared

Announcement

iPhone App



Download
iPhone, iPad
application



A free application to browse and search the journal's content is now available for iPhone/iPad. The application provides "Table of Contents" of the latest issues, which are stored on the device for future offline browsing. Internet connection is required to access the back issues and search facility. The application is Compatible with iPhone, iPod touch, and iPad and Requires iOS 3.1 or later. The application can be downloaded from <http://itunes.apple.com/us/app/medknow-journals/id458064375?ls=1&mt=8>. For suggestions and comments do write back to us.