

Age estimation in Indian children and adolescents in the NCR region of Haryana: A comparative study

Swati Gupta,
Monica Mehendiratta,
Shweta Rehani,
Madhumani Kumra,
Ruchi Nagpal¹,
Ramakant Gupta²
*Departments of Oral Pathology
and Microbiology,
¹Public Health Dentistry and
²Oral and Maxillofacial Surgery
Sudha Rustagi College of
Dental Sciences and Research,
Faridabad, Haryana, India*

Address for correspondence:
Dr. Swati Gupta,
696, Sector 15-A,
Near Vidya Mandir School,
Faridabad - 121 007,
Haryana, India.
E-mail: dr.swatijkgupta@gmail.
com

Abstract

Introduction: Age estimation is a preliminary step in the identification of an individual. It is a crucial and often most critical step for forensic experts. The assessment has been standardized utilizing common dental diagnostic x-rays, but most such age-estimating systems are European population-based and their applicability has not been determined in the context of the Indian population. **Aims and Objectives:** To assess the applicability and to compare the methods of dental age estimation by Demirjian's method and the same method as modified by Willems (i.e. the Willems method) in Indian children of the National Capital Region (NCR). Also, to find a correlation among skeletal maturity using the Cervical vertebrae maturation index (CVMI), dental maturity, and chronological age in the same population. **Materials and Methods:** This cross-sectional study was conducted using dental radiographs of 70 orthodontic patients (37 males, 33 females) in the age range 9-16 years selected by simple random sampling. pantomogram were used to estimate dental age by Demirjian's method and the Willems method using their scoring tables. Lateral cephalograms were used to estimate skeletal maturity using CVMI. The latter was compared with Demirjian's stage for mandibular left second molar. **Results:** Overestimation of age among males by 0.856 years and 0.496 years was found by Demirjian's and the Willems methods, respectively. Among females, both the methods underestimated the age by 0.31 years and 0.45 years, respectively. Demirjian's stage G corresponded to CVMI stage 3 in males and stage 2 in females. **Conclusion:** In our study, the Willems method has proved to be more accurate for age estimation among Indian males, and Demirjian's method for Indian females. A statistically significant association appeared between Demirjian's stages and CVMI among both males and females. Our study recommends the derivation of a regression formula by studying a larger section of the Indian population instead of applying the European system of age estimation directly to the Indian scenario.

Key words: Cervical Vertebrae Maturation Index, Demirjian's method, dental age, Willems method

Access this article online

Website:
www.jfds.org

DOI:
10.4103/0975-1475.172453

Quick Response Code



Introduction

Age estimation is important not only for identifying unknown dead bodies in the context of criminal situations or mass disasters but also for living individuals in medicolegal/criminal cases such as rape, child labor, child marriage, and accidents in cases of legal immigrants.

In a forensic situation, age estimation is a preliminary step in the identification of an individual. Dental records when properly maintained with complete data can help identification, e.g. through radiographs [such as pantomogram and lateral cephalograms], casts, and prostheses.

There are various age-estimating systems available for the determination of chronological age, dental age, skeletal age, and sexual age. Ideally, age estimation should be a conclusion of the critical outcome of all the available possible data put into the systems and considered separately, if the forensic situation provides enough such evidence. Often, dental age estimation is considered superior owing to its lower variability, the ease of the procedure, and especially when the availability of other evidence/remains is scarce.

There are various methods of dental age assessment, some based on clinical eruption, such as Bean^[1] 1914, Beik^[2] 1913, Cateli^[3] 1928, Norms derived from Logan and Kronfeid's data^[4] 1933, Schour and Masler^[5] 1940, Hurme's^[6] 1946, Clements, Davies Thomas and Pickett's^[7] 1957, Nanda^[8] 1960, Steggerda and Hill^[9] 1942, and Stones *et al.*^[10] 1951. Others are based upon association between emergence and root formation, such as Brauer and Bahador^[11] 1942, Gran and Lewis^[12] 1957, Gleiser and Hunt^[13] 1955, Gron^[14] 1962, Haaviko^[15] 1970, and Shumaker and El Hadary^[16] 1960.

Demirjian's^[17] method of age assessment is a popular method, as it considers the developmental stages of teeth, which are less likely to be affected by endocrinal, systemic, or other factors that affect the eruption of teeth, but it is based only on a French-Canadian population. On the other hand, Willems^[18] modified the scoring system of Demirjian's^[17] method for a Belgian population by using weighted analysis of variance (ANOVA).

The different stages of tooth development, i.e. dental maturity, have been widely investigated^[19] as an indicator of skeletal maturity. The cervical vertebrae maturation index (CVMI) is one of the easiest and most commonly used skeletal maturity indices. To find out the same, skeletal

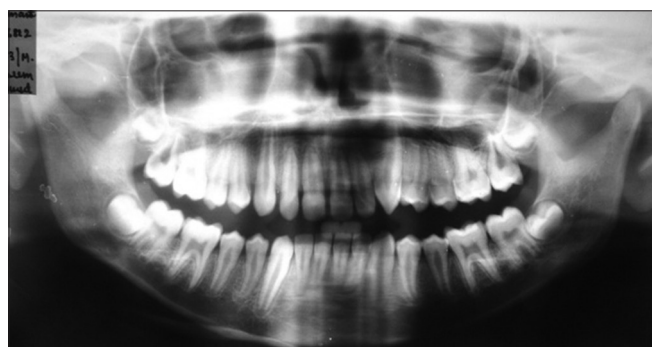


Figure 1: pantomogram exhibiting teeth in various stages of calcification

maturity using CVMI has been assessed in our study to find a correlation with dental maturity.

To the best of our knowledge, no studies had been conducted for age estimation on the population in the Faridabad district of Haryana, India. In our study, we used both the Demirjian's and the Willems methods to find their applicability for an Indian population. In addition, CVMI was used to find a correlation between skeletal and dental maturity.

Materials and Methods

In this cross-sectional study, panoramic and lateral cephalogram radiographs of 70 patients (37 males, 33 females) were obtained from their pretreatment records after visiting the Department of orthodontics at the Sudha Rustagi College of Dental Sciences and Research, Faridabad, India. The study sample was selected by simple random sampling.

The patients included were 9-16 years of age, with normal overall growth and development, absence of any congenital anomalies or bone lesions, no systemic illness, and no previous extraction of permanent teeth.

Evaluation of dental maturity and dental age on pantomogram

For estimation of dental age, left mandibular teeth were used from central incisor to second molar.^[17] Teeth calcification statuses as seen on OPG [Figure 1] were rated according to the index described by Demirjian *et al.*^[17] [Figure 2], and each tooth was assigned a letter between "A" and "H."

The scores were added to obtain a dental maturity score, which was later converted to dental age using the tables given by Demirjian *et al.*^[17] The dental age thus obtained was termed Demirjian's age^[17] (DA). Similarly, dental age was also estimated by the Willems method, using tables given by Willems,^[18] and this age was termed Willems age (WA).

The Demirjian's stage, i.e. between "A to H" for the mandibular left second molar was also noted and termed the Dental Index [Demirjian Index (DI)].

Evaluation of cervical vertebrae maturity on lateral cephalogram

CVMI were evaluated by classifying the cervical vertebrae

Stage	Characteristics
Stage A	Calcification of single occlusal points without fusion of different calcifications.
Stage B	Fusion of mineralization points; the contour of the occlusal surface is recognizable.
Stage C	Enamel formation has been completed at the occlusal surface, and dentin formation has commenced. The pulp chamber is curved, and no pulp horns are visible.
Stage D	Crown formation has been completed to the level of the cemento-enamel junction. Root formation has commenced. The pulp horns are beginning to differentiate, but the walls of the pulp chamber remain curved.
Stage E	The root length remains shorter than the crown height. The walls of the pulp chamber are straight, and the pulp horns have become more differentiated than in the previous stage. In molars, the radicular bifurcation has commenced to calcify.
Stage F	The walls of the pulp chamber now form an isosceles triangle, and the root length is equal to or greater than the crown height. In molars, the bifurcation has developed sufficiently to give the roots a distinct form.
Stage G	The walls of the root canal are now parallel, but the apical end is partially open. In molars, only the distal root is rated.
Stage H	The root apex is completely closed (distal root in molars). The periodontal membrane surrounding the root and apex is uniform in width throughout.

Figure 2: Demirjian's stages of tooth calcification

into six groups according to their maturation stages as seen on lateral cephalogram [Figure 3] using the classification of Hassel and Farman^[20] [Figure 4].

Statistics

Statistical analysis was done using Microsoft Office Excel 2007 and SPSS software (version 15, SPSS Inc., Chicago, IL, US). Descriptive analysis was done by determining the means and standard deviation of the chronological age [Table 1] and the estimated dental age [Tables 2 and 3] for both males and females.

Instances of the difference between the chronological age and the estimated dental age by both the methods (Demirjian’s and Willems) were statistically tested by using the student’s *t*-test [Tables 2 and 3]. The correlation between chronological age and estimated dental age by the two methods (Demirjian’s and Willems) was found using the interclass correlation coefficient (ICC) [Table 4].

The dental and skeletal maturity was compared by using Pearson’s Chi-square test [Table 5].

Results

Demirjian’s method

The mean age difference [Table 2] found using Demirjian’s method was +0.856 years (SD=1.69) and -0.31 years (SD=1.55) among males and females, respectively. The age difference was statistically significant for males (*P* = 0.003) and insignificant among females (*P* = 0.302).

Willems method

The mean age difference [Table 3] found using Willems method was + 0.496 years (SD = 1.88) and -0.45 years (SD = 1.61) among males and females, respectively. The age difference was found to be insignificant among both males and females, with *P* values of 0.085 and 0.173, respectively.

Comparison between the Demirjian’s method and the Willems method

Statistically, nearly similar correlation was found among males between the chronological age and the dental age by both the methods (Demirjian’s and Willems). In females, slightly higher correlation appeared between the chronological age and the dental age by Demirjian’s method than by Willems method [Table 4].

Stage	Characteristics
Stage 1 (initiation)	Very significant amount of adolescent growth expected (80% to 100%). C ₂ , C ₃ , and C ₄ inferior vertebral body borders are flat. Vertebrae are wedge-shaped. Superior vertebral borders are tapered posterior to anterior.
Stage 2 (acceleration)	Significant amount of adolescent growth expected (65% to 85%). Concavities are developing in the inferior borders of C ₂ and C ₃ . The inferior border of C ₄ is flat. The bodies of C ₃ and C ₄ are nearly rectangular in shape.
Stage 3 (transition)	Moderate amount of adolescent growth expected (25% to 65%). Distinct concavities are seen in the inferior borders of C ₂ and C ₃ . A concavity is beginning to develop in the inferior border of C ₄ . The bodies of C ₃ and C ₄ are rectangular in shape.
Stage 4 (deceleration)	Deceleration of adolescent growth spurt. Small amount of adolescent growth expected (10% to 25%). Distinct concavities in the inferior borders of C ₂ , C ₃ , and C ₄ . C ₂ and C ₃ are nearly square in shape.
Stage 5 (maturation)	Final maturation of the vertebrae takes place during this stage. Insignificant amount of adolescent growth expected (5% to 10%). Accentuated concavities of inferior vertebral body borders of C ₂ , C ₃ , and C ₄ . C ₂ and C ₃ are square in shape.
Stage 6 (completion)	Adolescent growth is completed (little or no growth expected). Deep concavities are seen in inferior border of C ₂ , C ₃ , and C ₄ . C ₂ and C ₃ heights are greater than widths.

Figure 3: CVMI stages as described by Hassel and farman

Correlation between dental and skeletal maturity

Highly significant correlation between dental and skeletal maturity (*P* < 0.001) was found among both males and females. CVMI stage 2 showed a 66.6% correlation with DI stage G in males and 100% in females. CVMI stage 3 revealed 100% correlation with stage G in males and 66.63% in females. CVMI stage 4 showed a correlation of 50% with stage G and H in males and of 60% with stage G and 30% with stage H in females [Table 5].

Discussion

In forensic situations, OPGs and lateral cephalograms can serve as useful tools for age estimation because of their easy accessibility (being the common radiographic investigations in any dental problem). Also, these cannot be manipulated or tempered, and are very easy to preserve for record maintenance. Moreover, ease of recognizing stages of tooth development and availability were the practical reasons for utilizing OPGs and lateral cephalograms to assess dental age.

Numerous studies have evaluated various age estimation methods on populations abroad and found Demirjian’s method to be the most reliable due to its accuracy and precision.^[20] Studies revealed statistically significant differences between chronological age and dental age, with differences of 0.73 and 0.51 years,^[21] 0.68 and 0.62 years,^[22] 0.4 and 0.6 years,^[23] and 0.25 and 0.23 years^[24] among boys and girls, respectively.

In the present study, a mean difference of 0.8 years in males and 0.3 in females between the estimated dental and chronological ages was found, but the age difference was found to be statistically significant in males and insignificant in females. Thus, in accordance with our study, Demirjian’s method should not be applied to Indian males.

Demirjian’s method has good reproducibility^[24] and is based on the stages of tooth development, which are unaffected by

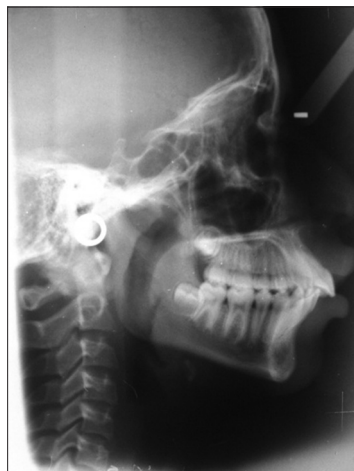

Figure 4: Lateral cephalogram showing CVMI stage 3

Table 1: The mean and standard deviations of age for both males and females

Gender	N%	Mean (SD)	P
Males	37	13.62 (2.17)	0.23
Females	33	14.31 (2.62)	
Total	70	13.949 (2.40)	

SD: Standard deviation

Table 2: The comparison between chronological age and dental age estimated by Demirjian's method in males and females

Gender	Mean chronological age	Demirjian's age (SD)	Mean age difference	P
Males	13.62	14.47 (1.69)	0.856	0.003
Females	14.31	13.99 (1.55)	-0.31	0.302

Table 3: The comparison between chronological age and dental age estimated by Willems method in males and females

Gender	Mean chronological age	Willems age (SD)	Mean age difference	P
Males	13.62	14.11 (1.88)	0.496	0.085
Females	14.31	13.86 (1.61)	-0.45	0.173

Table 4: An agreement between chronological age and dental age using Demirjian's method and the Willems method

Gender	ICC ^D (95% CI)	ICC ^W (95%CI)
Males	0.789 (0.58,0.89)	0.78 (0.58,0.89)
Females	0.80 (0.60,0.90)	0.77 (0.54,0.88)

ICC: Interclass correlation coefficient, ICC^D: Agreement between chronological age and dental age using Demirjian's method, ICC^W: Agreement between chronological age and dental age using Willems method, CI: Confidence interval

Table 5: An association between dental index and cervical vertebrae maturation index for both male and females

CVMI ↓	Males n (%)				Females n (%)			
	E	F	G	H	F	G	H	
1	1 (33.33)	2 (66.66)	0	0	0	0	0	
2	0	3 (33.33)	6 (66.66)	0	0	4 (100)	0	
3	0	0	9 (100)	0	0	7 (63.63)	4 (36.36)	
4	0	0	5 (50)	5 (50)	1 (10)	6 (60)	3 (30)	
5	0	0	0	4 (100)	0	1 (25)	3 (75)	
6	0	0	0	2 (100)	0	0	4 (100)	
P value	<0.001				<0.001			

DI: Dental index, CVMI: Cervical vertebrae maturation index

systemic or endocrinal factors,^[17] thus making it a relatively reliable study adopted for age estimation.

The Willems method is a modification of Demirjian's method and has been found to be more accurate^[18] than the latter. Willems *et al.*,^[18] modified Demirjian's method by creating new tables, from which a maturity score could be directly expressed in years. This made the method simpler, yet retaining the advantages of Demirjian's technique. Also, the Willems method reduced the overestimation of dental age, which was not statistically different from zero in a Belgian population.^[18] Maber *et al.*,^[25] also found the

estimated dental age by using the Willems method to be more accurate than Demirjian's method. Thus the former became a second method of choice for age estimation.

Using the Willems method, our study revealed an overestimation of age by 0.4 years among males and an underestimation of 0.4 years among females. The age differences among both males and females were found to be statistically insignificant, thus the Willems method is applicable to both Indian males and females.

A statically higher correlation between the dental age and the chronological age by Demirjian's method was found among females, therefore, we consider Demirjian's method over the Willems method for the estimation of age in Indian females.

Although both the methods (Demirjian's and Willems) revealed a similar correlation with chronological age in males, but the age difference between chronological age and estimated dental age by Willems method was insignificant. Therefore, the Willems method is considered over Demirjian's method for the estimation of age in Indian males.

Various studies^[26-29] have reported high correlations between the stages of tooth calcification and skeletal maturity indicators, which would probably allow the forensic odontologist or dentist to assess age using lateral cephalograms also. On the other hand Lewis and Garn,^[30] Garn *et al.*,^[31] and Tanner^[32] reported insignificant correlations.

There are many studies that have used the mandibular canine or the third molars for dental age assessment,^[31,32] but these have a few limitations. Root formation and apex closure of mandibular canines are completed by 13 years of age, but active skeletal growth is exhibited till the 16-17 age range in children.^[33] The third molars are common congenitally missing teeth in human dentition.^[33] Thus, these teeth are less reliable for age estimation.

In our study, the mandibular second molars were used to assess dental maturity, as its development continues for a long period and apex closure occurs by the age of 16 years in normal children.^[33] In addition, the estimation errors are less frequent in the mandibular molars than in the maxillary molars as maxillary molar roots generally overlap with anatomic structures such as the zygomatic arch, maxillary sinus, or inferior border of zygomatic process, which makes the observation of roots difficult.^[32,33]

Studies^[26,27,34-36] have exhibited that CVMI stages appear earlier in girls than boys,^[32] and a similar trend was seen in the present study as well. It revealed a statistically significant correlation between CVMI and DI in both males

and females. The DI stage G corresponded to CVMI stage 3 in males and stage 2 in females.

The significant finding in our study was the correlation between the DI stage G and CVMI stage 3 in males and stage 2 in females. It implies that the lateral cephalograms can also be used to help assess the dental maturity and thus give an idea of the age of an individual.

The limitation of the present study includes limited sample size, which is why further study is recommended to find better correlation between the skeletal, chronological, and dental ages. Further, the study recommends the derivation of the regression formula separately for males and females by studying a larger size of the Indian population instead of applying European systems of age estimation directly to Indian children and adolescents.

Conclusion

The Willems method estimated age more accurately in Indian males, while Demirjian's method appeared more accurate in Indian females in the NCR. Correlation between the skeletal maturity and the dental age was reflected by the association of DI stage G with CVMI stage 3 in males and 2 in females.

Acknowledgments

This study is dedicated to Late Dr. Jatinder Kumar Gupta. Further, we the authors are thankful to Dr. Gurkeerat Singh, Head of Department of Orthodontics, Sudha Rustagi College of Dental Sciences and Research and his postgraduate students Dr. Naseem Joy Garg, Dr. Sonali Grover, Dr. Dayashanker, Dr. Nupur, and Dr. Piyush Mudgal for kindly providing radiographs used in the study. We wholeheartedly thank Dr. Shekher Grover and Dr. Shweta Bhadana, who provided us a portion of the literature required for the study. We would also like to express our enormous gratitude toward Dr. Ramakant Gupta, Dr. Manju Gupta, and Dr. Rahul Grover for all their ceaseless support and encouragement during the study.

References

1. Bean RB. Eruption of teeth as physiological standard for testing development. *Pedagog Sem.* 1914;21:620.
2. Beik AK. *Physiological Age School Entrance.* Vol 20. California: Pedagogical Seminary; 1913. p. 277-321.
3. Kamalanathan GS, Hauck HM. Dental development of children in a Siamese Village, Bang Chan, 1953. *J Dent Res* 1960;39:455-61.
4. Logan WH, Kronfeld R. Development of the human jaws and surrounding structures from birth to the age of fifteen years. *J Am Dent Assoc.* 1933;20:379-427.
5. Schour I, Massler M. Studies in tooth development: The growth pattern of human teeth, part II. *J Am Dent Assoc.* 1940;27:1918-31.
6. Hurme VO. Ranges of normalcy in the eruption of permanent teeth. *J Dent Child.* 1949;16:11-5.
7. Climents EM, Davies-Thomas E, Pickett KG. Time of eruption of permanent teeth in British children at independent, rural, and urban schools. *Br Med J.* 1957;1:1511-3.
8. Nanda RS. Eruption of human teeth. *Am J Orthod.* 1960;46:363-78.
9. Steggerda M, Hill TJ. Eruption time of teeth among whites Negroes, and Indians. *Am J Orthod.* 1942;28:361-70.
10. Stones HH, Lawton FE, Brancy ER, Hartley HO. Time of eruption of permanent teeth and time of shedding of deciduous teeth. *Br Dent J* 1951;90:1-7.
11. Brauer JC, Bahador MA. Variations in calcification and eruption of the deciduous and permanent teeth. *J Am Dent Assoc* 1942;29:1373-87.
12. Gran SM, Lewis AB. Relationship between the sequence of calcification and the sequence of eruption of mandibular molar and premolar teeth. *J Dent Res* 1957;36:992-5.
13. Gleiser I, Hunt EE Jr. The permanent mandibular first molar: Its calcification, eruption and decay. *Am J Phys Anthropol* 1957;13:253-82.
14. Gron AM. Prediction of tooth emergence. *J Dent Res* 1962;41:573-85.
15. Haavikko K. The formation and the alveolar and clinical eruption of the permanent teeth. An orthopantomographic study. *Suom Hammaslaak Toim* 1970;66:103-70.
16. Shumaker DB, Hadry MS. Roentgenographic study of eruption. *J Am Dent Assoc* 1960;61:535-41.
17. Demirjian A, Goldstein H, Tanner JM. A new system of dental age assessment. *Hum Biol* 1973;45:211-27.
18. Willems G, Van Olmen A, Spiessens B, Carels C. Dental age estimation in Belgian children: Demirjian technique revisited. *J Forensic Sci* 2001;46:893-5.
19. Hassel B, Farman AG. Skeletal maturation evaluation using cervical vertebrae. *Am J Orthod Dentofacial Orthop* 1995;107:58-66.
20. Hagg U, Matsson L. Dental maturity as an indicator of chronological age: The accuracy and precision of three methods. *Eur J Orthod* 1985;7:25-34.
21. Liversidge HM, Speechly T, Hector MP. Dental maturation in British children: Are Demirjian's standards applicable? *Int J Paediatr Dent* 1999;9:263-9.
22. Eid RM, Simi R, Friggi MN, Fisberg M. Assessment of dental maturity of Brazilian children aged 6 to 14 years using Demirjian's method. *Int J Paediatr Dent* 2002;12:423-8.
23. Leurs IH, Wattel E, Aartman IH, Eddy E, Prahl- Andersen B. Dental age in Dutch children. *Eur J Orthod* 2005;27:309-14.
24. Mani SA, Naing L, John J, Samsudin AR. Comparison of two methods of dental age estimation in 7-15 year old Malays. *Int J Paediatr* 2008;18:380-8.
25. Maber M, Liversidge HM, Hector MP. Accuracy of age estimation of radiographic methods using developing teeth. *Forensic Sci Int* 2006;159 (Suppl 1):S68-73.
26. Krailassiri S, Anuwongnukron N, Dechkunakorn S. Relationship between dental calcification stages and skeletal maturity indicators in Thai individuals. *Angle Orthod* 2012;72:155-66.
27. Uysal T, San Z, Ramoglu St, Basciftci FA. Relationships between dental and skeletal maturity in Turkish subjects. *Angle Orthod* 2004;74:657-64.
28. Mappes MS, Harris EF, Behrents RG. An example of regional variation in the tempos of tooth mineralization and hand-wrist ossification. *Am J Orthop Dentofacial Orthop* 1992;101:145-51.
29. Chertkow S. Tooth mineralization as an indication of the pubertal growth spurt. *Am J Orthod* 1980;77:79-91.
30. Lewis AB, Garn SM. The relationship between tooth formation and other maturational factors. *Angle Orthod* 1960;30:70-7.
31. Garn SM, Lewis AB, Bonne B. Third molar formation and its development course. *Angle Orthod* 1962;32:270-9.

32. Cho SM, Hwang CJ. Skeletal maturation evaluation using mandibular third molar development in adolescents. *Korean J Orthod* 2009;39:120-9.
33. Kumar S, Singla A, Sharma R, Viridi MS, Anupam A, Mittal B. Skeletal maturation evaluation using mandibular second molar calcification stages. *Angle Orthod* 2012;82:501-6.
34. Mittal S, Singla A, Viridi M, Sharma R, Mittal B. Co-relation between determination of skeletal maturation using cervical vertebrae and dental calcification stages. *Internet J Forensic Sci* 2009;4 (2) Available from: <https://www.ispub.com/IJFS/4/2/5855>. [Last accessed on 2015 Sep 11].
35. Rai B. Relationship of dental and skeletal radiograph: Maturity indicator. *Internet J Biol Anthropol* 2007;2 (1) Available from: <https://www.ispub.com/IJBA/2/1/9842>. [Last accessed on 2015 Sep 11].
36. Rai B, Anand S. Relationship of hand wrist and panoramic radiographs. *Internet J Forensic Sci* 2007;3:(1) Available from: <https://www.ispub.com/IJFS/3/1/6562>. [Last accessed on 2015 Sep 11].

How to cite this article: Gupta S, Mehendiratta M, Rehani S, Kumra M, Nagpal R, Gupta R. Age estimation in Indian children and adolescents in the NCR region of Haryana: A comparative study. *J Forensic Dent Sci* 2015;7:253-8.

Source of Support: This study has not been supported financially or in any other form by anybody,

Conflict of Interest: None declared