

Are teeth evidence in acid environment

Makesh Raj, Karen Boaz¹,
Srikant N¹

Department of Oral and
Maxillofacial Pathology, Tagore
Dental College and Hospital,
Chennai, Tamil Nadu, ¹Manipal
College of Dental Sciences,
Mangalore, Manipal University
Karnataka, India

Address for correspondence:

Dr. Makesh Raj,
Department of Oral and
Maxillofacial Pathology, Tagore
Dental College and Hospital,
Ratinamangalam, Vandalar Post,
Chennai, Tamil Nadu, India.
E-mail: akeshe_raj@rediffmail.com

Introduction

Teeth being the most durable structures of the human body, persist even after the other skeletal structures have decayed.^[1,2] Thus serving as a clue in determination of age and sex for forensic investigators. Criminal minds use commercially available acids to destroy the body as a whole or its part to avoid personal identification of the victim.

Morphological changes in tooth can be used in identification, sex determination and age estimation of a victim. Different morphological methods have been proposed for age estimation by Gustafson (1950), Dalitz (1962), Bang and Ramm (1970), Johanson (1971), Maples (1978) and Solheim (1993).^[3] Variations in tooth size are greatly influenced by genetics and environmental factors. Morphological assessment of tooth can aid in sex determination. Most commonly used dimensions are buccolingual and mesiodistal measurement.^[4] Karaman (2006) used diagonal measurement of teeth for sex

Abstract

Aim: Teeth are the most durable structures that resist destruction more than skeletal tissue. Commercially available acids can be used to destroy the body or a part, to mask human identification. The present study examines the effect of caustic acids on human dentition. **Materials and Methods:** Ten upper anterior teeth each were immersed in 37% hydrochloric acid (conc. HCl), 65% nitric acid (conc. HNO₃) and 96% sulfuric acid (conc. H₂SO₄). Teeth were retrieved, washed in distilled water, dried, photographed and radiographed at intervals of 15 min, 30 min, 1 hr, 3 hr, 5 hr and 8 hr. **Results:** Teeth placed in conc. HCl and conc. HNO₃ dissolved completely after 8 hours, while that placed in conc. H₂SO₄ retained its morphology and radiographic dimension even after 8 hours. **Conclusion:** Hence teeth can serve as a tool in identification (age estimation and sex determination) of the victim when in contact with conc. H₂SO₄.

Key words: Age estimation, caustic acids, masking identity, sex determination, teeth

determination.^[5] However, measuring the dimensions may cause some difficulty in patients with crowding, rotations, fillings and prosthetic replacements.^[4,5] All these methods use samples in an unsectioned or sectioned manner.


Dental radiograph serves as a key in forensic odontology of all age. Kvaal and Solheim were the first to use size of the pulp in full mouth radiograph for age estimation.^[1,6] Extraction of tooth cast no importance in age assessment by radiograph. Hence radiographic method is a noninvasive method of age assessment.^[7] Although biochemical methods of age estimation have shown bigger confidence interval over morphological and radiographic methods, they are still reliable.

A study was conducted with an aim to observe the morphological changes of the human teeth exposed to acid environment and to obtain dimensions that can aid in the identification process of victims immersed in acid.

Materials and Methods

Thirty noncarious upper anterior teeth were obtained for the study. In view of the chemical alteration already present the tooth affected with caries was excluded from the study.

Thirty-seven percent hydrochloric acid (conc.HCl), 65% nitric acid (conc. HNO₃) and 96% sulfuric acid (conc. H₂SO₄)

Access this article online	
Website: www.jfds.org	Quick Response Code 
DOI: 10.4103/0975-1475.114536	

are of concern in this study. Ten samples were immersed in 25 ml of each acid solution and observed for 8 hours. Teeth were retrieved at intervals of 15 min, 30 min, 1 hr, 3 hr, 5 hr and 8 hours from the caustic environment, washed in distilled water, dried, photographed, radiographed and again placed in their corresponding acids. Each of specimen's morphology was observed at time intervals of 15 min, 30 min, 1 hr, 3 hr, 5 hr and 8 hours.

Radiographic dimensional assessment for root length (R), tooth length (T), maximum pulp length (P) and root and pulp width at CEJ (A), centre of tooth (C) and midway between the above two measurement (B) was measured at the stipulated intervals.^[1]

Results

Morphological observation of samples

For a tooth placed in conc. HCl mild crack was observed within 15 min. Progression of crack was seen in 30 min and at the end of an hour morphology of the tooth got dissipated. Tooth completely dissolved in 8 hr [Figure 1].

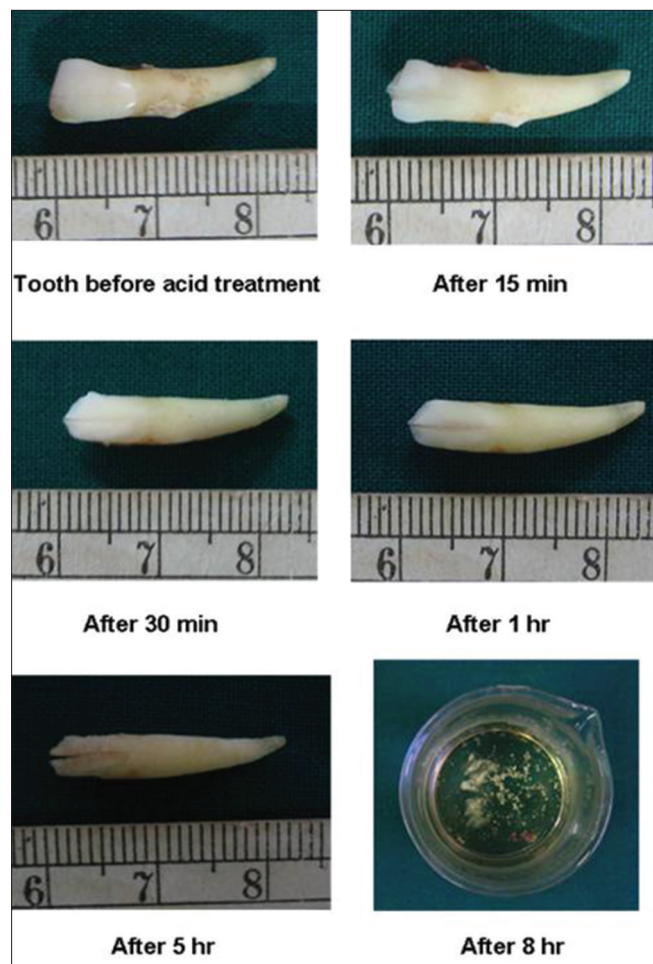


Figure 1: Morphological appearance of teeth treated with conc. HCl at different interval

Tooth placed in conc. HNO₃ showed mild yellowish discoloration in the root in 15 min. Formation of crack and its development was obvious in an hour. As the previous solution, tooth completely dissolved at the 8th hr [Figure 2].

No obvious changes were noticed in 30 min for the tooth placed in conc. H₂SO₄. Chalky white appearance with dissolution of enamel was observed with in 3 hr. Morphology of the tooth was retained even after 8 hr [Figure 3].

Radiographical observation of the sample

Specimen in conc. HCl, conc. HNO₃ showed vast changes in dimensions for every time interval. Tooth placed in conc. H₂SO₄ showed very less change in the dimensions [Figures 4-6]. Dimensions of teeth placed in all three acids are shown in Table 1.

Discussion

Acid attacks on victims are a very common practice among gangsters in South-east Asia. Acids are known to be used to erase the personal identification. In such a case, various tissues aid in determination of age and gender of the affected.

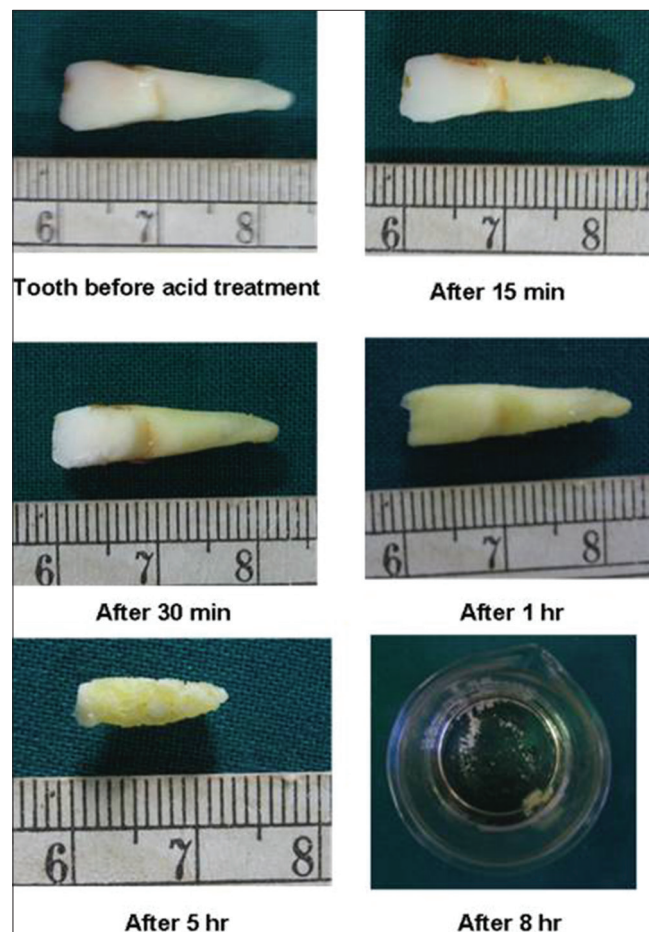


Figure 2: Morphological appearance of teeth treated with conc. HNO₃ at different interval

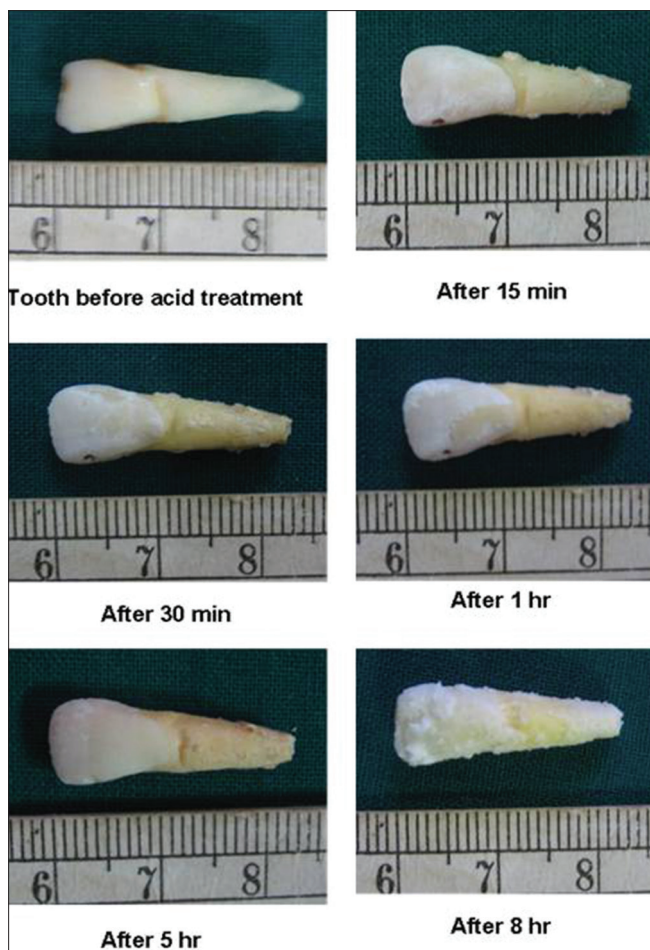


Figure 3: Morphological appearance of teeth treated with conc. H₂SO₄ at different interval

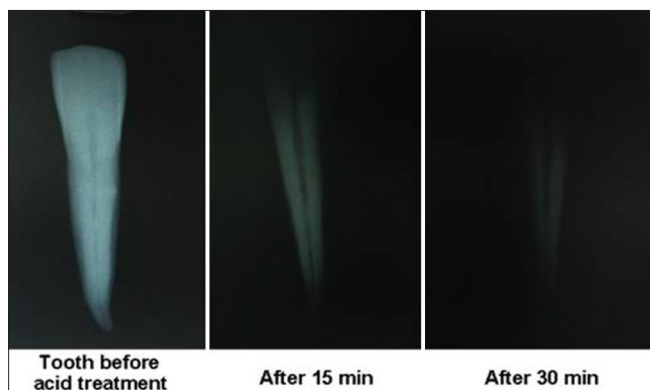


Figure 4: Radiographical appearance of teeth treated with conc. HCl at different interval

Human dentition serves an viable evidence in this scenario.^[1]

The choice of teeth paves a way for attaining the diagnosis. Teeth like incisors and canine are less complicated to measure and premolars to withstand trauma and fire. Hence incisors and canine are best chosen for morphological assessment and premolars for radiographic age estimation. Maxillary anterior were used in this study, since they

Table 1: Mean radiographic dimensions of tooth placed in acid

Time	Sulphuric acid						Hydrochloric acid						Nitric acid						
	Tooth length (mm) (T)	Root length (mm) (R)	Pulp length (mm) (P)	Width at CEJ (mm) (A)	Width at center (mm) (C)	Width at midway (mm) (B)	Tooth length (mm) (T)	Root length (mm) (R)	Pulp length (mm) (P)	Width at CEJ (mm) (A)	Width at center (mm) (C)	Width at midway (mm) (B)	Tooth length (mm) (T)	Root length (mm) (R)	Pulp length (mm) (P)	Width at CEJ (mm) (A)	Width at center (mm) (C)	Width at midway (mm) (B)	
				Root Pulp	Root Pulp	Root Pulp				Root Pulp	Root Pulp	Root Pulp							
Initial	21.5	15	17	5	3.5	0.5	24	15	19	4	3	0.5	23	15	18	4	2.5	0.5	3
15 min	21	14.5	16.5	5	3.5	0.5	17	13	17	3.5	2.5	0.5	19	15	18	4	2.5	0.5	3
30 min	21	14.5	16.5	5	3.5	0.5	15	13	15	3.5	2.5	0.5	17	15	17	3.5	2	0.5	2.5
1 hr	21	14.5	16.5	5	3	0.5	13	13	13	3	2	0.5	13	13	13	3.5	2	0.5	2.5
3 hr	20.5	13.5	16	4	2.5	0.5	12	12	12	3	2	0.5	12	12	12	3	2	0.5	2
5 hr	20.5	13.5	16	4	2.5	0.5	8	8	8	2	1.5	0.5	8	8	8	1.5	1	0.5	1
8 hr	20.5	13.5	16	4	2.5	0.5	3	3	3	2	1.5	0.5	3	3	3	1.5	1	0.5	1
																			Tooth completely dissolved

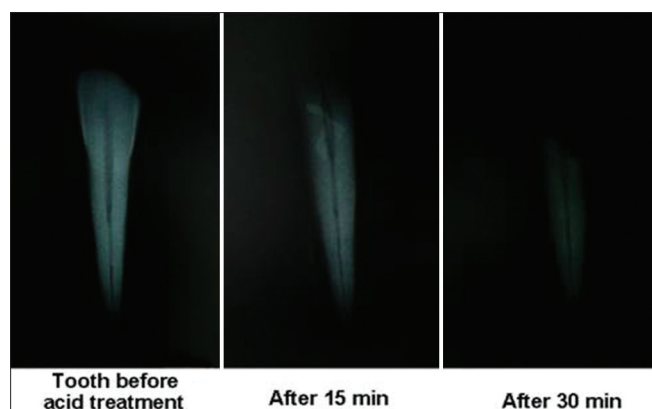


Figure 5: Radiographical appearance of teeth treated with conc. HNO_3 at different interval

are most likely to be affected by acids compared to other teeth.^[8,9] As decayed teeth may alter the effect of acid, hence teeth with periodontal problem have been set as samples.

Before commencement of the experiment, it was hypothesized that teeth immersed would dissolve irrespective of acid solution making identification impossible. But on the contrary the sample in conc. H_2SO_4 retained its morphology even after 8 hours.

From the above observation it is concluded that teeth does not react the same way in all acid environment. Teeth placed in the conc. HCl and conc. HNO_3 forms soluble salts of calcium chloride and calcium nitrate, respectively, making them to dissolve in toto. Tooth placed in conc. H_2SO_4 forms insoluble calcium sulfate salt failing to dissolve completely forming an insoluble precipitate.^[9,10] Hence, human dentition can serve as great evidence when a person is affected with concentrated sulfuric acid aiming at destruction of personal identification.

Dental radiographs play a vital role in age estimation of all age. Kvaal and Solheim have combined both radiographic and morphological measurements to estimate the age of an individual. Kvaal *et al.* used measurements such as pulp/tooth length, pulp/root length, tooth/root length, pulp/root width at CEJ, midway of root and midway.^[1] It is well known that age estimation based on the pulp/tooth volume ratio generates promising results.^[6,11,12]

The above-mentioned measurements were taken from tooth samples at the stipulated intervals and dimensions were measured and recorded. From the study tooth immersed in conc. H_2SO_4 showed very little variation or 1mm in the tooth length in the dimension even after 8 hrs as shown in Table 1. The samples in the HNO_3 and HCl showed reduction in the height of 15-16 mm thus rendering it useless for analysis.

By the above observation a positive diagnosis can be made with a tooth, when a victim's body is treated with conc.

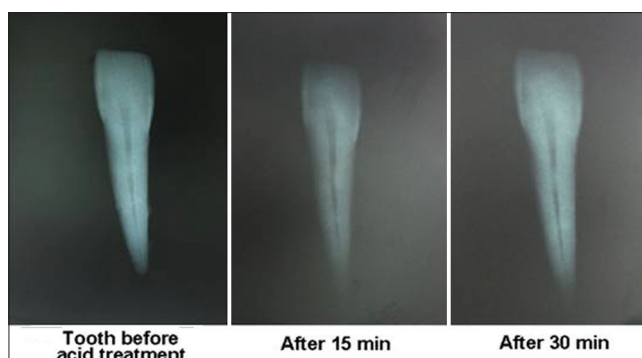


Figure 6: Radiographical appearance of teeth treated with conc. H_2SO_4 at different interval

H_2SO_4 . But if the bodies are immersed in the conc. HCl and conc. HNO_3 it will be difficult to make a positive diagnosis with teeth as a factor.

Limitation of this study is that effects of acids surrounding the teeth, dental restoration and prosthesis have not been assessed.

References

1. Kvaal SI, Kolltveit KM, Thomsen Ib O, Solheim T. Age estimation of adult from radiographs. *Forensic Sci Int* 1995;74:175-85.
2. Cameriere R, Ferrante L, Belcastro MG, Bonfiglioli B, Rastelli E, Cingolani M. Age estimation by pulp/tooth ratio in canines by peri-apical X-rays. *J Forensic Sci* 2007;52:166-70.
3. Stavrianos CH, Mastagas D, Stravianou I, Karaïskou O. Dental age estimation of adults. A review of methods and principals. *Res J Med Sci* 2008;2:258-68.
4. Ates M, Karaman F, Iscan MY, Erdem TL. Sexual differences in Turkish dentition. *Legal Med* 2006;8:288-92.
5. Karaman F. Use of diagonal teeth measurements in predicting gender in a Turkish population. *J Forensic Sci* 2006;51:630-5.
6. Willems G. A review of the most commonly used dental age estimation technique. *J Forensic Odontostomatol* 2001;19:9-17.
7. Cameriere R, Ferrante L, Cingolani M. Variation in pulp/Tooth area ratio as an indicator of age: A preliminary study. *J Forensic Sci* 2004;49:317-9.
8. Pretty IA, Sweet D. A look at forensic dentistry-Part 1: The role of teeth in the determination of human identity. *Br Dent J* 2001;190:359-66.
9. Mazza A, Merlati G, Savio C, Fassina G, Menghini P, Danesino P. Observation of dental structure when placed in contact with acids: An experimental study. *J Forensic Sci* 2005;50:406-10.
10. Jadhav K, Gupta N, Mujib BR, Amberkar VS. Effect of acids on the teeth and its relevance in postmortem identification. *J Forensic Dent Sci* 2009;1:93-8.
11. Singaraju S, Sharada P. Age estimation using pulp/tooth area ratio: A digital image analysis. *J Forensic Dent Sci* 2009;1:37-41.
12. Šebečić V, Hoch A, Sabalić M. How to estimate dental age in paleodontology. *Bull Int Assoc Paleodont* 2010;4:27-32.

How to cite this article: Raj M, Boaz K, Srikant N. Are teeth evidence in acid environment. *J Forensic Dent Sci* 2013;5:7-10.

Source of Support: Nil, **Conflict of Interest:** None declared