


# Patterns - “A crime solver”

Nagasupriya A,  
Raghu Dhanapal,  
Reena K, Saraswathi TR,  
Ramachandran CR  
*Department of Oral and  
Maxillofacial Pathology,  
Vishnu Dental College,  
Bhimavaram, Andhra Pradesh,  
India*

**Address for correspondence:**  
*Dr. Raghu Dhanapal,  
Department of Oral and  
Maxillofacial Pathology,  
Vishnu Dental College,  
Bhimavaram, Andhra Pradesh,  
India.  
Email: raghudhanapal@gmail.  
com*

## Introduction

The moral and professional obligation of a dental surgeon to mankind is not only to serve in examination, investigation, diagnosis, and treatment of oral and oro-facial lesions of local origin, but also to serve in other community services and legal matters. Dental surgeon has an active role in various objectives of forensic dentistry like age and sex determination, personal identification of unknown deceased person, analyzing bite marks as evidence, participating in mass disaster, giving evidence in child abuse etc. His/her role in personal identification and criminal investigation is

Access this article online	
<b>Website:</b> www.jfds.org	<b>Quick Response Code</b> 
<b>DOI:</b> 10.4103/0975-1475.85282	

## Abstract

**Objective:** This study is intended to analyze the predominant pattern of lip and finger prints in males and females and to correlate lip print and finger print for gender identity. **Materials and Methods:** The study sample comprised of 200 students of Vishnu Dental College, Bhimavaram, Andhra Pradesh, 100 males and 100 females aged between 18 to 27 years. Brown/pink colored lip stick was applied on the lips and the subject was asked to spread it uniformly over the lips. Lip prints were traced in the normal rest position of the lips with the help of cellophane tape. The imprint of the left thumb was taken on a white chart sheet and visualized using magnifying lens. While three main types of finger prints are identified, the classification of lip prints is simplified into branched, reticular, and vertical types. Association between lip prints and finger prints was statistically tested using Chi-square test. **Results:** This study showed that lip and finger patterns did not reveal statistically significant results within the gender. The correlation between lip and finger patterns for gender identification, was statistically significant. In males, branched type of lip pattern associated with arch, loop, and whorl type of finger pattern was most significant. In females, vertical lip pattern associated with arch finger pattern and reticular lip pattern associated with whorl finger patterns were most significant. **Conclusion:** We conclude that a correlative study between the lip print and finger print will be very useful in forensic science for gender identification.

**Key words:** Cheiloscopy, dermatoglyphics, sex determination

very much important, as his/her evidence would be very much useful in law and justice.

The wrinkles and grooves on the labial mucosa, called as sulci laborium, forms a characteristic pattern called as lip prints. The study of lip prints is known as cheiloscopy.<sup>[1]</sup> The wrinkles and grooves visible on the lips have been named by Tsuchihashi as ‘sulci labiorum rubrorum’.<sup>[2]</sup> The term “fingerprint” predominantly means an impression of the epidermal ridges of the fleshy distal portion of a finger formed by applying ink and pressing the finger on paper and is used as means of establishing identification.<sup>[3]</sup> Study of finger prints is known as dermatoglyphics.<sup>[4]</sup> Lip prints are unique to an individual like finger prints. The present study was aimed to analyze the predominant pattern of lip and finger prints and to identify any correlation between the finger print and lip print patterns that could help forensic odontologists to solve the crime.

## Materials and Methods

The study sample comprised of 200 students of

Vishnu Dental College, Bhimavaram, Andhra Pradesh, 100 males and 100 females aged between 18 to 27 years. Individuals free from any pathology of the lips or fingers were included in this study. The procedure of taking lip and finger prints was explained to the participants and consent of all the individuals were obtained.

**Materials**

Materials used were brown and pink colored lip stick, cellophane tape, white graph sheet, blue inked stamp pad, and magnifying lens.

**Method**

The subject was asked to rinse the mouth with water and lips were allowed to dry. Brown/pink colored lip stick was applied on the lips and the subject was asked to spread it uniformly over the lips by gentle movement of the lips. Over the lip stick, the glued portion of the cellophane tape was dabbed first in the center and then pressed uniformly over the corner of the lips. Lip prints were traced in the normal rest position of the lips. The cellophane tape was then stuck to the white chart sheet for permanent record purpose. The imprint of the left thumb was taken on a white chart sheet. They were visualized using magnifying lens. While studying the lip prints, each subject's lips were divided into four quadrants and were allotted the digits 1-4 in a clockwise sequence starting from subject's upper right. These prints were examined using magnifying glass, classified, and analyzed.

**Classification**

**Analysis of lip prints**

Although there are classifications proposed by Santos<sup>[5]</sup> and Suzuki and Tsuchihashi<sup>[2]</sup> for lip prints, we devised a simplified method which is as follows:

1. Type I – Vertical pattern  
(Grooves running vertically to the full length or partially across the lips)
2. Type II – Branched pattern  
(Grooves exhibiting branching)
3. Type III – Reticular pattern  
(Grooves intersecting or criss-crossing one another)

**Analysis of finger prints**

Finger print classification of Michael Kucken<sup>[4]</sup> was used.

1. Loop pattern. 2. Arch pattern. 3. Whorl pattern.

Statistical analysis was done using Chi-square test. P value ≤ 0.05 is considered as statistically significant.

**Results**

A total of 200 individuals were included in the study, comprising of 100 males and 100 females in the age group of 18 to 27 years. Lip print and finger print patterns observed in this study are shown in Figures 1 and 2.

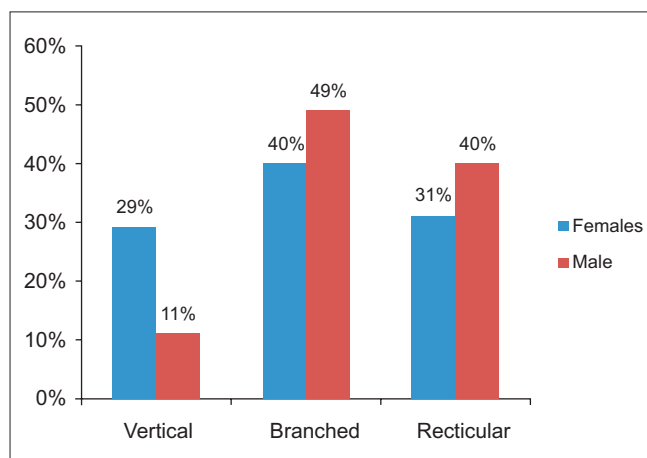
**Results revealed the following observations**

The overall patterns of lip prints both in males and females and finger prints in both the sexes were given in Graphs 1 and 2, respectively. Lip and finger patterns did not reveal statistically significant results within the gender.

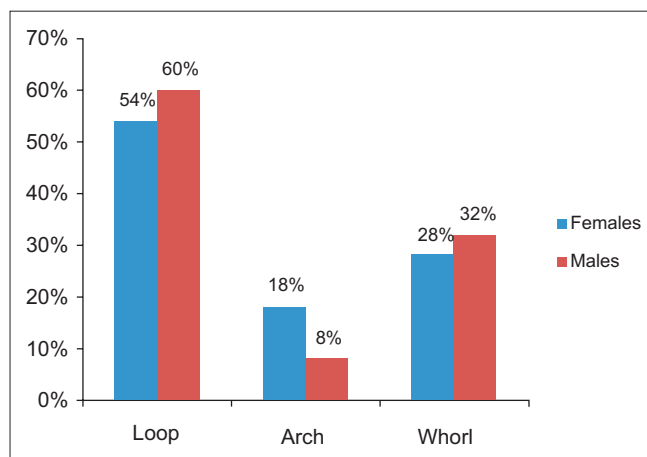
The overall correlation of lip prints with finger prints in



Figure 1: Types of finger prints



Graph 1: Association between gender and lip pattern



Graph 2: Association between gender and finger pattern

males is given in Table 1. In males, branched type of lip pattern shows statistical significance. Though it is associated with all three finger patterns, branched lip print associated with arch finger print is highly significant ( $P=0.001$ ) followed by loop finger print pattern ( $P=0.005$ ) and whorl finger print pattern ( $P=0.006$ ).

The overall correlation of lip prints with finger prints in females is given in Table 2. In females, reticular and vertical lip patterns show statistical significance. Vertical lip pattern associated with arch finger pattern shows high statistical significance ( $P=0.009$ ) followed by reticular lip pattern associated with whorl finger pattern ( $P=0.05$ ).

## Discussion

Lip prints and finger prints form a pattern that is unique for each individual. Comparative study of lip prints and finger prints for the interpretation in personal identification is scanty in the literature. Personal identification is very much necessary for unknown deceased person in homicide, suicide, mass disasters, accidents etc. It is also necessary for living individuals like missing person due to amnesia and culprits hiding his/her identity. In dead persons, usually the

personal identification is made by comparing an already existing ante mortem record with that of post mortem records whose identity is required.<sup>[6]</sup> In live persons if the patterns bank is available where the data is collected and recorded, it will be useful for identifying the individual.

Apart from the teeth and their restorations, soft tissues of oral cavity may help for personal identification. Among the soft tissues, lip prints can be recorded and used as evidence in personal identification and criminal investigation. If the lip print is identified and traced from the material during investigation, it can be compared with the suspected persons. In deceased persons, lip prints have to be obtained within 24 hours to prevent them from post mortem changes.<sup>[7]</sup>

Unlike the lip prints, the use of finger prints in personal identification is very much popular in criminal investigations. However, lip prints could also contribute in evidence seeking process of forensic study. The lipstick marks left over certain objects are characterized by their permanence and persistence. They could be utilized for investigations even after a lapse of few days. Alvarez and associates have shown that these prints can be developed and visualized using agents such as aluminium powder and magnetic

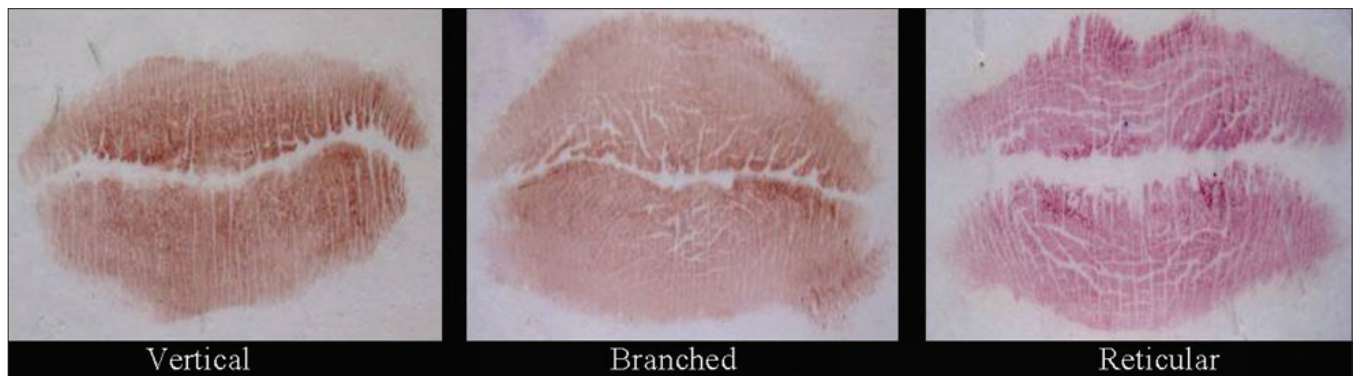

Figure 2: Types of lip prints

Table 1: Correlation of lip patterns with finger patterns in males (n=100)

Lip print	Finger pattern						Total (n)
	Loop		Arch		Whorl		
	n - %	P value	n - %	P value	n - %	P value	
Vertical	5 (45.45)	0.387	2 (18.18)	1.425	4 (36.36)	0.065	11
Branched	29 (59.18)	0.005	4 (8.16)	0.001	16 (32.65)	0.006	49
Reticular	26 (65)	0.166	2 (5)	0.45	12 (30)	0.50	40
Total (n)	60		8		32		100

Table 2: Correlation of lip patterns with finger patterns in females (n=100)

Lip print	Finger pattern						Total (n)
	Loop		Arch		Whorl		
	n - %	P value	n - %	P value	n - %	P value	
Vertical	13 (44.83)	0.451	5 (17.24)	0.009	11 (37.93)	1.021	29
Branched	23 (57.5)	0.090	8 (20)	0.08	9 (22.5)	0.43	40
Reticular	18 (58.06)	0.09	5 (16.13)	0.06	8 (25.81)	0.05	31
Total (n)	54		18		28		100

powder.<sup>[8]</sup> The present study has been aimed to correlate the lip pattern with that of finger pattern for personal identification.

The vermilion border has minor salivary glands and the edges of the lips have sebaceous and sweat glands. The secretions of oil and moisture from these enable development of latent lip prints in most crime scenes, analogous to latent finger prints, where there was a close contact between the victim and culprit.<sup>[9]</sup> Sivapathasundharam *et al* have cautioned the need for consideration of major trauma to the lips and surgical treatment rendered to correct any abnormality that affects the size and shape of the lips thereby altering the pattern and morphology of grooves.<sup>[10]</sup> It is also necessary to select the proper lip stick so that there will not be any smudge and difficulties in taking the lip prints.

Finger prints as a form of identification have been used at least since 7000 to 6000 BC by the ancient Assyrians and Chinese. Bricks used in houses in the ancient city of Jericho were sometimes imprinted by pairs of thumb prints. In the mid 1800's, scientific studies were begun and established two critical characteristics of finger prints that are true till to this day: no two finger prints from different fingers have been found to have the same ridge pattern and finger print ridge patterns are unchanging throughout the life. These studies led to the use of finger prints for criminal identification, first in Argentina in 1896, then at Scotland Yard in 1901, and to other countries in the early 1900's. Computer processing of finger prints began in the early 1960s with the introduction of computer hardware that could reasonably process these images. Since then, automated finger print identification systems (AFIS) have been employed widely among law enforcement agencies throughout the world. In the late 1990s, the introduction of inexpensive finger print capture devices and the development of fast, reliable matching algorithms have set the stage for the expansion of finger print matching to personal use.<sup>[11]</sup>

There are various theories proposed for finger pattern formation. Kollmann in 1883 speculated that ridge pattern is formed as a result of a folding process induced by differential growth. This idea was promoted by Bonnevie in 1920 who stated that there will be intense cell proliferation in the basal layer of the epidermis which results in cylindrical cells. Finally, epidermis evades the dermis, resulting in the formation of primary ridges. There is evidence that primary ridge system changes till 16<sup>th</sup> week of pregnancy and after 16<sup>th</sup> week it becomes permanent and remains unchanged throughout the life. Even in superficial skin injuries, finger patterns will be reformed without any change because they are encoded at the interface between dermis and epidermis.

Another view regarding the formation of primary ridges is linked to the nervous system. Dell and Munger in

1986 stated that before ridge formation, finger tips are innervated by a hexagonal pattern of axons determining the growth of primary ridges formation. But, this theory was refuted by Morohunfolo *et al.* 1992 who proved the formation of primary ridges even in the absence of innervations.<sup>[4]</sup> Till now, there is no commonly accepted mechanism for ridge formation and all views are contradictory to one another.

Although there are various classifications proposed till now,<sup>[2,5]</sup> we have devised a new classification system for lip prints as it is simple and useful for comparative analysis. In this system, we included both partial and full vertical lip pattern under one category as vertical lip print pattern (type I). To prevent overlap, we unified the intersected and reticular lip prints because these patterns are almost similar (type III). The branched lip print constitutes the type II pattern. Various studies have been done till now on lip prints for gender identification. Sharma *et al.* had concluded that undetermined lip pattern (27.5%) in males, vertical and partial vertical lip patterns in females (25%), are common.<sup>[12]</sup> Saraswathi *et al.* reported that intersecting pattern was most common both in males (39.5%) and females (36.5%)<sup>[6]</sup> and their finding is similar to that of Sivapathasundharam *et al.*<sup>[10]</sup> In the study of Gondivkar *et al.* criss cross lip pattern was reported in 51.05% males and 37.06% branched lip pattern in females.<sup>[13]</sup> In our study, the predominant pattern is branched type, 49% in males and 40% in females followed by reticular pattern, 40% in males and 31% in females and vertical pattern 11% in males and 29% in females [Graph 1]. Study of lip prints conducted in Uttar Pradesh,<sup>[12]</sup> Maharashtra,<sup>[13]</sup> and Tamil Nadu<sup>[6,10]</sup> showed difference in predominance of patterns in males and females.

All the above studies reported the pattern of predominance of lip prints in males and females. In the statistical analysis conducted by Gondivkar *et al.*, gender identification by lip prints showed a *P* value of 0.65 in females and 0.95 in males.<sup>[13]</sup> In spite of simplifying the lip print classification and increasing the sample size, we observed that lip print analysis does not show statistical significance between the genders. Therefore, we wanted to design a correlative study of lip with finger prints for gender identification.

This is the first comparative study done between the lip prints and finger prints. Our results showed that, in males, branched lip pattern associated with arch finger print is highly significant ( $P=0.001$ ) followed by loop finger print pattern ( $P=0.005$ ) and whorl finger print pattern ( $P=0.006$ ). In females, vertical lip pattern associated with arch finger pattern showed high statistical significance ( $P=0.009$ ) followed by reticular lip pattern associated with whorl finger pattern ( $P=0.05$ ). With the availability of lip and finger patterns and correlating both the types, it is possible to suggest the gender in forensic scenario.

## Conclusion

There are many studies on lip patterns, finger patterns and palatal rugae patterns etc. for gender determination, but correlative studies are scanty. This is the first study done by correlating two patterns i.e., lip print with finger print. We have introduced a new classification for lip prints as it is simple and useful for comparative analysis. In this study, lip and finger prints did not reveal statistical significance within the gender, but correlating the lip prints with finger prints, high statistical significance was revealed. We conclude that a correlative study between the lip print and finger print will be very useful in forensic science for personal identification.

## References

1. Shafer, Hine, Levy. Shafer's text book of oral pathology, 6th ed. Noida, India: Elsevier; 2009. p. 871-97.
2. Suzuki K, Tsuchihashi Y. A new attempt of personal identification by means of lip print. J Indian Dent Assoc 1970;42:8-9.
3. Gyula G. A short history and some results of the dermatoglyphic studies in Hungary. Acta Biol Szeged 2000;44:135-8.
4. Kucken M, Newell AC. Finger print formation. J Theor Biol 2005;235:71-83.
5. Santos M. Queiloscopia: A supplementary stomatological means of identification. Int Microform J Leg Med 1967;2:P:64-68.
6. Saraswathi TR, Mishra G, Ranganathan K. Study of lip prints. J Forensic Dent Sci 2009;1:28-31.
7. Kavitha B, Einstein A, Sivapathasundharam B, Saraswathi TR. Limitations in forensic odontology. J Forensic Dent Sci 2009;1:8-10.
8. Alvarez Segui M, Miquel Feucht M, Castello Ponce A, Verdu Pascual F. Persistent lipsticks and their lip prints: new hidden evidence at the crime scene. Forensic Sci Int 2000;112:41-7.
9. Ball J. The current status of lip prints and their use for identification. J Forensic Odontostomatol 2002;20:43-6.
10. Sivapathasundharam B, Ajayprakash P, Sivakumar G. Lip prints (cheiloscopy). Indian J Dent Res 2001;12:234-7.
11. Lawrence OG, Veridicom I, Chatham NJ. Finger print verification. 3<sup>rd</sup> ed. California Elsevier; 1998. p. 1-23.
12. Sharma P, Saxena S, Rathod V. Cheiloscopy: The study of lip prints in sex identification. J Forensic Dent Sci 2009;1:24-7.
13. Gondivkar SM, Indurkar A, Degwekar S, Bhowate R. Cheiloscopy for sex determination. J Forensic Dent Sci 2009;1:56-60.

**How to cite this article:** Nagasupriya A, Dhanapal R, Reena K, Saraswathi TR, Ramachandran CR. Patterns - "A crime solver". J Forensic Dent Sci 2011;3:3-7.

**Source of Support:** Nil, **Conflict of Interest:** None declared

JFDS is now indexed with PubMed

NCBI Resources How To

PubMed.gov  
U.S. National Library of Medicine  
National Institutes of Health

Search: PubMed  
RSS Save search Limits Advanced search Help

Journal of Forensic Dental Sciences[Jour] AND 2010[pdat] Search Clear

Display Settings: Abstract, 20 per page, Sorted by Recently Added Send to:

Results: 9

J Forensic Dent Sci. 2010 Jan;2(1):37-43.

1. **Effects of high temperature on different restorations in forensic identification: Dental samples and mandible.**  
Patidar KA, Parwani R, Wanjari S.  
Department of Oral and Maxillofacial Pathology, Modern Dental College and Research Center, Airport Road, Gandhi Nagar, Indore, Madhya Pradesh, India.

**Abstract**  
**INTRODUCTION:** The forensic odontologist strives to utilize the charred human dentition throughout each stage of dental evaluation, and restorations are as unique as fingerprints and their radiographic morphology as well as the types of filling materials are often the main feature for identification. The knowledge of detecting residual restorative material and composition of unrecovered adjacent restoration is a valuable tool-mark in the presumptive identification of the dentition of a burned victim. Gold, silver amalgam, silicate restoration, and so on, have a different resistance to prolonged high temperature, therefore, the identification of burned bodies can be correlated with adequate qualities and quantities of the traces. Most of the dental examination relies heavily on the presence of the restoration as well as the relationship of one dental structure to another. This greatly narrows the research for the final identification that is based on postmortem data.  
**AIM:** The purpose of this study is to examine the resistance of teeth and different restorative materials, and the mandible, to variable temperature and duration, for the purpose of identification.  
**MATERIALS AND METHODS:** The study was conducted on 72 extracted teeth which were divided into six groups of 12 teeth each based on the type of restorative material. (Group 1 - unrestored teeth, group 2 - teeth restored with Zn(3)(PO(4))(2), group 3 - with silver amalgam, group 4 with glass ionomer cement, group 5 - Ni-Cr-metal crown, group 6 - metal ceramic crown) and two specimens of the mandible. The effect of incineration at 400°C (5 mins, 15 mins, 30 mins) and 1100°C (15 mins) was studied.  
**RESULTS:** Damage to the teeth subjected to variable temperatures and time can be categorized as intact (no damage), scorched (superficially parched and discolored), charred (reduced to carbon by incomplete combustion) and incinerated (burned to ashes).

PMID: 21189989 [PubMed - in process] PMID: PMC3009553 Free PMC Article  
Related citations

Free Full Text @ www.jfds.org  
FREE full text article in PubMed Central