

# Effect of acids on the teeth and its relevance in postmortem identification

Kiran Jadhav,  
Nidhi Gupta,  
BR Ahmed Mujib,  
Vikram S Amberkar  
*Department of Oral and Maxillofacial Pathology, Bapuji Dental College, Davangere, Karnataka, India*

**Address for correspondence:**  
*Dr. Kiran Jadhav,  
Department of Oral & Maxillofacial Pathology,  
Bapuji Dental College & Hospital, Davangere,  
Karnataka, India.  
E-mail: drnidhi5599@gmail.com  
DOI: 10.4103/0974-2948.60381*

## Abstract

**Background:** The nature of crime is changing day by day and the forensic scientist is always facing new problems in the process of identification. For example, difficult though it may be to believe, criminals are now-a-days using acids to destroy bodies in order to avoid any personal identification. This is a matter of great interest to the forensic scientist. Is it possible to destroy the human body completely in an acid? If so, are there any means to identify the body? **Objectives:** The aim of this study was to identify the agent (acid) that is most likely to be used in such crimes and to find out if the morphological changes in the teeth could be used to deduce the approximate duration of time elapsed after immersion of a body in an acid. Since the natural teeth are most resistant to destruction they can persist for long after other skeletal structures have been destroyed by physical agents. The objective of study was to observe the morphological changes occurring in natural human teeth when they were kept immersed in an acid solution. **Materials and Methods:** Teeth were kept in 25 ml of aqueous solutions of three different acids and observed periodically for morphological changes. **Results:** The results showed that teeth could be completely dissolved in 37% hydrochloric acid (HCl) after 15 h of immersion, whereas in 65% nitric acid 20 h was required for complete dissolution. In the case of 96% sulphuric acid, the teeth reacted in a different manner. There was a residual precipitate observed at the bottom of the container after 144 h. It was possible to identify the characteristic morphological changes in the tooth until an advanced stage of degradation. **Conclusion:** Hydrochloric acid, nitric acid and sulfuric acid cause changes in the teeth and it is possible to deduce the approximate duration for which a body has been immersed in acid based on the changes observed.

**Key words:** Acids, chemical analysis, criminal psychology, decalcification of teeth, forensic science

## Introduction

The practice of destroying the human body by immersing it in an acid or some other caustic substance in order to avoid any personal identification is drawing a great deal of forensic interest these days. Crimes of this nature have been frequently reported in Italy.<sup>[1]</sup>

The forensic scientist needs to know whether it is possible to destroy the human body partially or totally by immersing it in an acid and, if so, how much time is necessary for its complete destruction. Another important question is whether there are any means of

identifying the deceased individual from the residual remains.

Literature search revealed that there are very few studies that have actually focused on the issue of destruction of the human body by chemical means and the issue of positive identification after acid dissolution. There is brief mention in the Italian journal *Archivio di Medicina Legale* of an experimental animal destruction in an acidic environment.<sup>[2]</sup>

The identification of dental remains is of prime importance when the deceased person is skeletonized, decomposed,

burned, or dismembered.<sup>[3]</sup> Joanna *et al.* have used various kinds of acids at various concentrations to compare the different decalcification methods for teeth.<sup>[4]</sup> It is well known that forensic odontological techniques help in the identification of an individual. Since the natural teeth are the most durable of all tissues, they can persist even long after other skeletal structures have been destroyed by physical agents. Further, it is now possible to extract DNA even decades after death. It is possible to employ these identification techniques until there has been complete destruction of the teeth.<sup>[1,5]</sup>

The aim of this study was to identify the acid that may be used by criminals for destruction of a human body and to find out the approximate time taken for total destruction of a body after immersion in an acid. The objective was to observe the morphological changes in natural human teeth when they were kept immersed in an acid.

## Materials and Methods

Sixty extracted human natural teeth were used for the study. All teeth were non-carious and had been extracted because of periodontal reasons. The teeth were kept in a dry environment at room temperature before the start of the experimental procedure.

The following acids were used in this study:

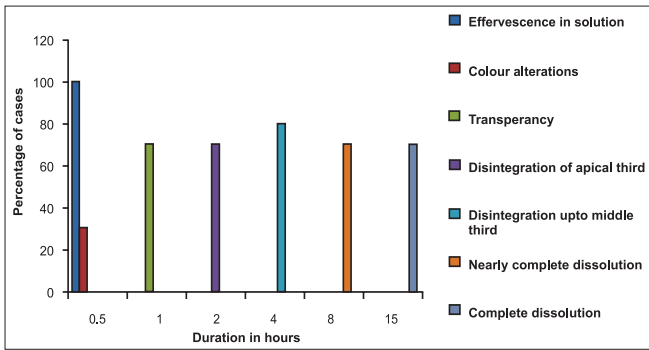
- Aqueous solution of hydrochloric acid (HCl): 25 ml (14.6 ml of 37% HCl + 10.4 ml of water)
- Aqueous solution of nitric acid (HNO<sub>3</sub>): 25 ml (16.25 ml of 65% HNO<sub>3</sub> + 8.75 ml of water)
- Aqueous solution of sulfuric acid (H<sub>2</sub>SO<sub>4</sub>): 25 ml (24 ml of 96 % H<sub>2</sub>SO<sub>4</sub> + 1 ml of water)

Teeth samples were divided into three groups as follows:

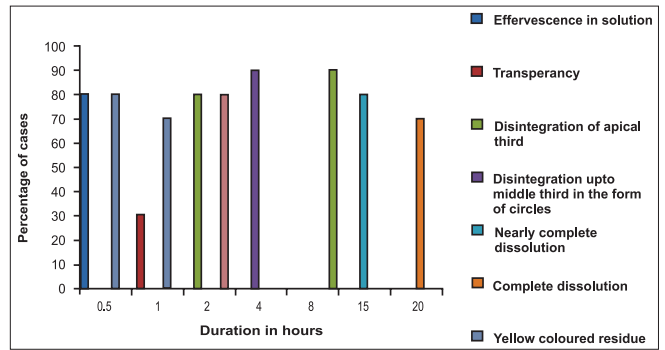
1. Hydrochloric acid (HCl) group: 20 extracted teeth

**Table 1: Morphological changes in teeth following immersion in an acid**

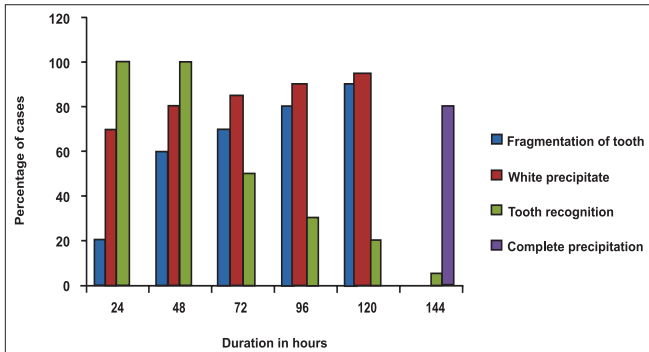
Duration	37% HCl	65% HNO <sub>3</sub>	96% H <sub>2</sub> SO <sub>4</sub>
0.5 h	Presence of effervescence in solution in 20/20 teeth (100%), with color alterations in 6/20 teeth (30%)	Presence of effervescence in solution in 16/20 teeth (80%), with yellow-colored residue deposited over the tooth in 16/20 teeth (80%)	No change
1 h	Transparency in 14/20 teeth (70%)	Yellow-colored residue deposited over the tooth in 14/20 teeth (70%), with transparency in 6/20 teeth (30%)	No change
2 h	Disintegration of apical third, without vertical lines on crown in 14/20 teeth (70%)	Disintegration of apical third, with vertical lines on crown in 16/20 teeth (80%)	No change
4 h	Disintegration up to middle third of root in 16/20 teeth (80%)	Disintegration of apical and middle third of root in the form of circles in 18/20 teeth (90%)	No change
8 h	Near complete dissolution in 14/20 teeth (70%)	Splitting of teeth in 18/20 teeth (90%)	Presence of white precipitate in (70%)
15 h	Complete dissolution in 14/20 teeth (70%)	Near complete dissolution in 16/20 teeth (80%)	White precipitate increased
20 h	-	Complete dissolution in 14/20 teeth (70%)	No change
24 h	-	-	White precipitate increased in 14/20 teeth (70%) with fragmentation of teeth in 4/20 (20%). Tooth was recognized in 20/20 teeth (100%)
48 h	-	-	White precipitate was increased in 16/20 teeth (80%), with fragmentation in 12/20 teeth (60%). The tooth was recognizable in 20/20 teeth (100%)
72 h	-	-	White precipitate was increased in 16/20 teeth (80%), with fragmentation in 14/20 teeth (70%). The tooth was still recognizable in 10/10 cases (50%)
96 h	-	-	White precipitate was increased in 16/20 teeth (80%), with fragmentation seen in 16/20 teeth (80%). Tooth was recognizable in 6/20 cases (30%)
120 h	-	-	White precipitate was increased in 18/20 teeth (90%), with fragmentation seen in 18/20 teeth (90%). Tooth was recognizable in 4/20 cases (20%)
144 h	-	-	Complete precipitate in 16/20 teeth (80%)



**Figure 1:** Morphological changes observed in teeth after immersion in 37% hydrochloric acid



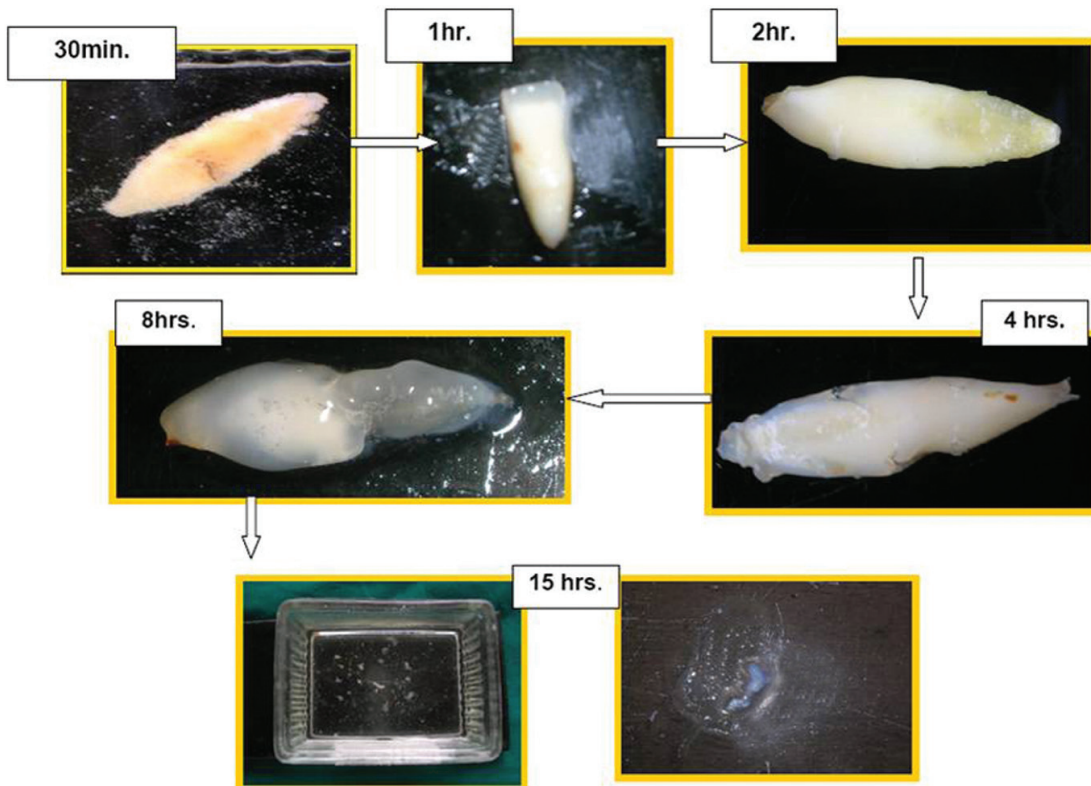
**Figure 2:** Morphological changes observed in teeth after immersion in 65% nitric acid



**Figure 3:** Morphological changes observed in teeth after immersion in 96% sulfuric acid

- Nitric acid (HNO<sub>3</sub>) group: 20 extracted teeth
- Sulfuric acid (H<sub>2</sub>SO<sub>4</sub>) group: 20 extracted teeth

The teeth were immersed separately in different containers containing the three different acids. At various intervals (30 min, 1 h, 2 h, 4 h, 8 h, 15 h, 20 h, 24 h, 48 h, 72 h, 96 h, 120 h, and 144 h) the samples were taken out of the container and examined for any morphological changes; they were then photographed and placed back in the containers. The specimens were under observation until they had completely dissolved or completely precipitated.



**Figure 4:** Sequential morphological changes observed in teeth after immersion in 37% hydrochloric acid

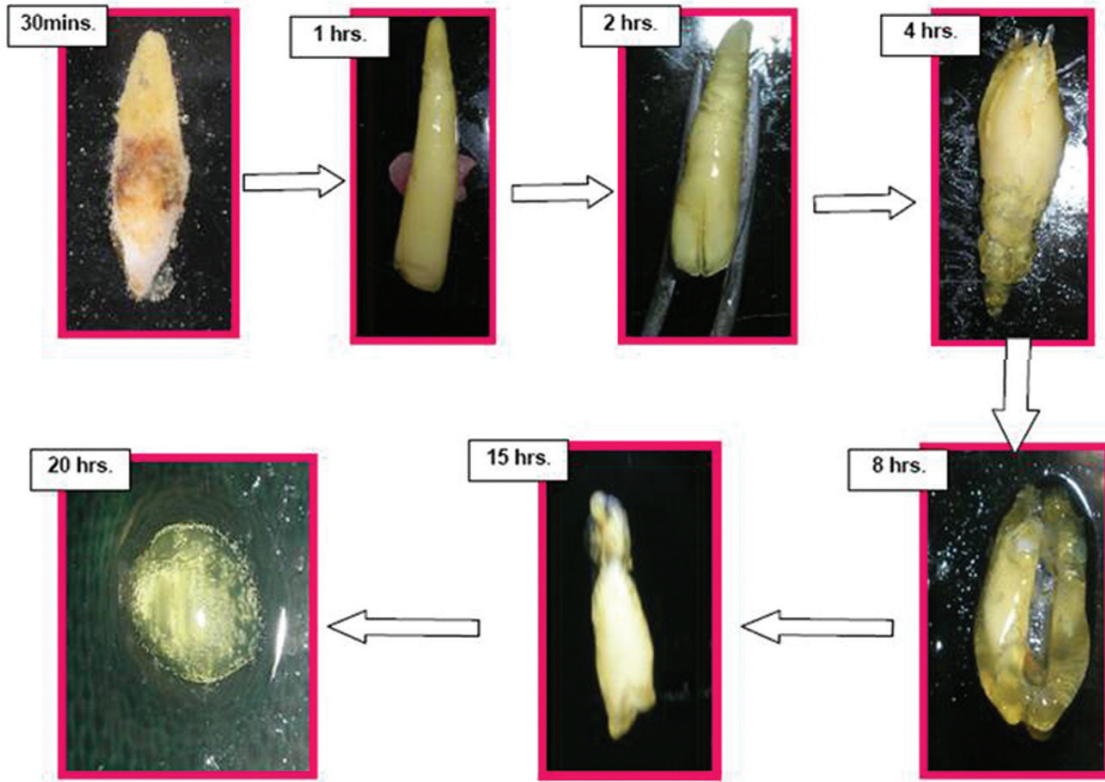


Figure 5: Sequential morphological changes observed in teeth after immersion in 65% nitric acid




Figure 6: Sequential morphological changes observed in teeth after immersion in 96% sulfuric acid



We used Fisher's exact test to assess the significance of the morphological changes seen in a particular acid at a particular time.

## Results

The morphological changes observed in teeth following immersion in 37% HCl, 65% HNO<sub>3</sub> and 96% H<sub>2</sub>SO<sub>4</sub> are tabulated in Table 1 and Figures 1-3.

### Hydrochloric acid group

There was effervescence in the solution after 30 min. Following this transparency was observed at the incisal edge; this progressively increased. After 4 h of immersion, disintegration of the crown and root was noticed. After 8 h of immersion in HCl, there was near complete dissolution of the tooth except for some remnants; these too had completely dissolved after 15 h [Figures 1 and 4].

### Nitric acid group

There was effervescence in the solution and a yellow-colored residue was deposited over the tooth. This progressively increased until it had covered the entire tooth specimen. There was initiation of disintegration, which first involved the crown in the form of a vertical line running cervico-incisally/occlusally. This was followed by the disintegration of the root, beginning at the apical portion and progressing to involve the middle third. The teeth then exhibited a tendency for vertical splitting. After 15 h of immersion there was nearly complete dissolution of the tooth except for some remnants, which too had completely dissolved by 20 h [Figures 2 and 5].

### Sulfuric acid group

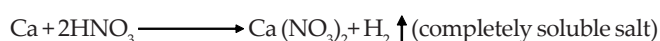
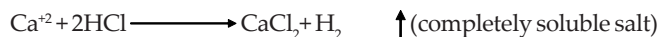
There was no alteration observed in the tooth structure up to 4 h of immersion. After 8 h there was a slight white precipitate deposited over the tooth and at the bottom of the container. This white precipitate increased with time. At 24 h there was fragmentation of the tooth, which increased with the passage of time. The tooth could be recognized up to 120 h after immersion. After 144 h, the tooth had completely disintegrated and only the precipitate was observed [Figures 3 and 6].

## Discussion


The use of teeth in this study is justified by the evidence that the natural teeth are the most durable of all tissues. They can persist even long after other skeletal structures have been destroyed by physical agents. We used non-carious teeth because caries can modify the behavior of teeth when they are placed in an acid; there may be acceleration of destruction process because of cavitation secondary to caries.<sup>[1,6]</sup>

In the case of 37% HCl and 65% HNO<sub>3</sub> the teeth were

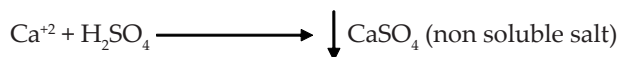
completely dissolved because of the chemical reaction that leads to the formation of a completely soluble salt.<sup>[1,6]</sup> The reaction is as follows:



In case of HNO<sub>3</sub>, the color change in the form of the yellow-colored deposit was mainly because of the nitrate formed in the chemical reaction, which is as follows<sup>[1,6]</sup>:



In the case of H<sub>2</sub>SO<sub>4</sub> there was no dissolution; instead, a white precipitate was formed. This was due to the formation of a non-soluble salt. The chemical reaction is as follows<sup>[1,6]</sup>:



Thus, there are clear differences in the destructive capacities of the different acids used in this study. The information derived in this study on the morphological changes observed in teeth after particular periods of immersion in an acid solution [Table 1] can be utilized for identification of the acid used and to deduce the approximate duration of immersion in the acid. The observed morphological changes may vary when the concentration of the acid used is different from that used in the present study; however, it must be noted that the concentrations that we have used are the ones that are most commonly available commercially.

Some other factors have also to be considered. For complete dissolution of body a minimum of 80–100 liters of acid is required.<sup>[1]</sup> Criminals will always be guided in their choice by ease of availability of the acid, cost, and efficiency of action. They will be more likely to use an acid that is easily available, cheap, and with the ability to destroy the body rapidly. Our investigations regarding the availability of the different acids showed that hydrochloric acid and sulfuric acid are more easily available commercially than is nitric acid. As far as the cost factor is concerned, hydrochloric acid is cheaper than sulfuric acid and nitric acid.<sup>[1]</sup>

Thus, based on these observations and our experimental results, we conclude that it is 37% hydrochloric acid that would be most likely used in such crimes. However, we must add that it is always advisable to carry out the usual biochemical tests to check which acid has been used.<sup>[6]</sup>

Recognizable morphological appearances of teeth persisted for 8 h in HCl, for 15 h in HNO<sub>3</sub>, and for up to 96 h in H<sub>2</sub>SO<sub>4</sub>. The morphological characteristics help the investigator in deciding whether the tooth is of human or animal origin, single or multi-rooted, deciduous or permanent, and restored or unrestored.

In situations where it is impossible to identify the dental

structures, other investigations can be considered,<sup>[1]</sup> such as:

- Chemical / histological analysis of the residues
- DNA analysis (mitochondrial) of the residues<sup>[5]</sup>
- Chemical analysis of the final residual solution

Various studies have described the use of dental records in forensic identification. However, for this, antemortem dental records must be available.<sup>[7]</sup> DNA analysis, which has brought about a revolution in the field of forensic science, including forensic dentistry, anthropology, and archeology, has made identification easier and more accurate.<sup>[8]</sup>

Admittedly, the present study does not take into account the influences of all possible factors that may be present in real life conditions. For example, the protection provided by the soft and hard tissues surrounding the teeth makes the root part more resistant to acid insults. Also, these findings obviously do not apply in the case of victims whose teeth have been replaced by prosthetic appliances.

## Conclusion

It is possible to destroy the human body completely in an acid. In crimes of this nature, hydrochloric acid is the most commonly used acid. Morphological changes in teeth can help the forensic investigator to deduce the time elapsed since immersion of the body in the acid. By keeping in mind the likely choices of the criminal and by observing the morphological changes in the teeth, it may be possible to deduce which acid has been used to destroy the body. However, the final decision on which acid has been used should be based on biochemical tests.

## Acknowledgment

We sincerely thank Dr. Yashwant, Assistant Professor, Department of Oral and Maxillofacial Surgery, College of Dental Sciences, Davangere, for his help and co-operation for the study. We also extend our thanks to Mr. A.G. Wandre, Professor, Department of Chemistry, Devchand College of Higher Education, Arjun Nagar, Maharashtra, and Dr U.R. Syed Mukith, Assistant Professor, Department of Oral Pathology, Rajiv Gandhi Dental College, Bangalore, for their help in formatting the manuscript.

## References

1. Mazza A, Meralati G, Savio C, Fassina G, Menaghini P, Danesino P. Observation of dental structure when placed in contact with acids: an experimental study. *J Forensic Sci* 2005;50:406-10.
2. Danesino P, Alonzo M, Carlesi G. Experimental evaluation of the biological samples dissolution performed by three different acids: preliminary results. *Archivio di Medicina Legale* 1998;1:23-6.
3. Avon SL. Forensic Odontology: The roles and responsibilities of the dentist. *J Can Dent Assoc* 2004;70:453-8.
4. Zappa J, Cieslik-Bielrcka A, Adwent M, Cieslik T, Sabat D. Comparison of different decalcification methods to hard teeth tissues morphological analysis. *Dent Med Probl* 2005;42:21-6.
5. Ginther C, Issel-Tarver L, King MC. Identification of DNA from human extracted teeth. *Nature Genetics* 1992;2:135-8.
6. Jeffery GH, Bassett J, Mendham J, Denney RC. Vogel's Textbook of Quantitative Chemical Inorganic Analysis. Britain: William Clowes publication ltd. 4<sup>th</sup> ed. 1962. p. 667.
7. Scott I, Fargrieve SL. SEM analysis of incinerated teeth as an aid in positive identification. *J Forensic Sci* 1994;39:557-65.
8. Presecki A, Brkic H, Primorac D, Drmic I. Methods of preparing the tooth for DNA isolation. *Acta Stomatol Croat* 2000;34:21-4.

**Source of Support:** Nil, **Conflict of Interest:** None declared

### Staying in touch with the journal

#### 1) Table of Contents (TOC) email alert

Receive an email alert containing the TOC when a new complete issue of the journal is made available online. To register for TOC alerts go to [www.jfds.org/signup.asp](http://www.jfds.org/signup.asp).

#### 2) RSS feeds

Really Simple Syndication (RSS) helps you to get alerts on new publication right on your desktop without going to the journal's website. You need a software (e.g. RSSReader, Feed Demon, FeedReader, My Yahoo!, NewsGator and NewzCrawler) to get advantage of this tool. RSS feeds can also be read through FireFox or Microsoft Outlook 2007. Once any of these small (and mostly free) software is installed, add [www.jfds.org/rssfeed.asp](http://www.jfds.org/rssfeed.asp) as one of the feeds.