

# Gender determination using barr bodies from teeth exposed to high temperatures

A. Vikram Simha Reddy,  
A. Ravi Prakash,  
Lakshmi Keerthana  
Killampalli,  
M. Rajinikanth,  
G. Sreenath, P. B. Sabiha<sup>1</sup>  
*Departments of Oral and  
Maxillofacial Pathology and  
<sup>1</sup>Conservative Dentistry and  
Endodontics, G Pulla Reddy  
Dental College and Hospital,  
Kurnool, Andhra Pradesh, India*

**Address for correspondence:**  
*Dr. Lakshmi Keerthana  
Killampalli,  
Department of Oral and  
Maxillofacial Pathology,  
G Pulla Reddy Dental College  
and Hospital, Kurnool - 518 007,  
Andhra Pradesh, India.  
E-mail: kheer9@gmail.com*

## Introduction

Human deaths are increasing day by day in spite of the latest medical facilities and amenities available. According to the National Crime Record Bureau, deaths due to accidental reasons have raised from 18.8% to 32.6% from 1980 to 2013. Among which 6–8% of deaths are only due to fire accidents.<sup>[1]</sup> Fire accidents in mass disasters might


occur in a variety of situations such as public transportation, communal and terror attacks, and electric accidents in areas of high population density. In such tragic and difficult situations, identification is possible, if the external characters are preserved.

Forensic identification can be done by general personal/social information, physical appearance (height,

## Abstract

**Context:** Gender determination forms a prime step in the forensic identification process. Teeth form a very important identification aid in forensic studies because they are protected by oral tissues and dental pulp is further protected by the mineralized constituents of the teeth. This allows the conservation and sustainable production of dental pulp to help sex determination in circumstances where other tissues cannot be analyzed like victims when exposed to high temperatures during fire accidents, explosions, and other mass disasters. **Aim:** The present study aimed at gender determination from pulpal tissue extirpated from teeth exposed to high temperatures. **Materials and Methodology:** The study consisted of sixty teeth samples, thirty male and thirty female. The teeth have been subjected to a series of temperatures of 37°C, 100°C, 200°C, 300°C, 400°C, 500°C, 600°C, 800°C, and 1000°C. The dental pulp is then obtained from these teeth, processed, stained, and checked for Barr bodies. **Statistical Analysis Used:** Descriptive statistical analysis has been used. **Results:** The results showed that pulp from the female teeth showed the presence of Barr bodies up to a maximum of 400°C, whereas the male pulpal tissue did not show the presence of any Barr bodies. With increase in temperatures, the cellularity of the connective tissue decreased but the average number of Barr body positive cells remained constant within the range of 19–20. **Conclusions:** Dental pulp acts as a potential source of gender determination when no other means of identification are available.

**Key words:** Barr bodies, dental pulp, gender determination, high temperatures

Access this article online	
<b>Website:</b> www.jfds.org	<b>Quick Response Code</b> 
<b>DOI:</b> 10.4103/0975-1475.206494	

This is an open access article distributed under the terms of the Creative Commons Attribution-NonCommercial-ShareAlike 3.0 License, which allows others to remix, tweak, and build upon the work non-commercially, as long as the author is credited and the new creations are licensed under the identical terms.

**For reprints contact:** reprints@medknow.com

**How to cite this article:** Reddy AV, Prakash AR, Killampalli LK, Rajinikanth M, Sreenath G, Sabiha PB. Gender determination using barr bodies from teeth exposed to high temperatures. *J Forensic Dent Sci* 2017;9:44.

weight, eye color, hair color, etc.), medical and dental history (fractures, diseases, missing teeth, dental crowns, fillings, etc.), distinguishing features like habits (e.g., pipe smoking), unique characteristics (such as scars, birthmarks, or tattoos), clothes, and other personal items the missing person was wearing or carrying when he or she was last seen or any circumstances related to the disappearance.<sup>[2]</sup> However, in conditions when the bodies are severely charred and when only cadavers or body remains are found, forensic identification from external morphologic characters and biochemical analysis becomes difficult or impossible.

Bones and teeth resist postmortem degradation and can withstand extreme environmental insult and incineration.<sup>[3]</sup> This is because of the durability of the bone and dental structures and the protection afforded by the soft tissues to them. Thus, making teeth as a useful source of forensic identification.

Gender determination is a prime step and has utmost importance in forensic identification. Gender determination can be done by a variety of methods such as observing the external genital characters, biochemical analysis, or molecular methods from chromosome analysis for amelogenin.

In 1949, Barr and Bertram determined that there was a difference between male and female cells. They found that, in female cells, there was a small chromatin condensation at the nuclei of nerve cells of cats (Barr *et al.*, 1950). This condensation is called as Barr body or Barr chromatin which is also found in found in bone cells, cells of the retina, and oral mucosal cells.<sup>[4]</sup>

Therefore, our study aimed to assess the usefulness of Barr bodies in gender determination from pulpal tissues extirpated from teeth which are subjected to high temperatures. Our study also aimed to ascertain the maximum temperatures up to which the teeth could be heated and could be used as a source for pulp tissue. Fire

accidents in mass disasters, crime scenarios are an alarming rise. In such conditions when personal identification becomes difficult, the bodies are totally charred or human remains are the only sources of identification left, we want to test the usefulness of dental pulpal tissue as a source of identification material.

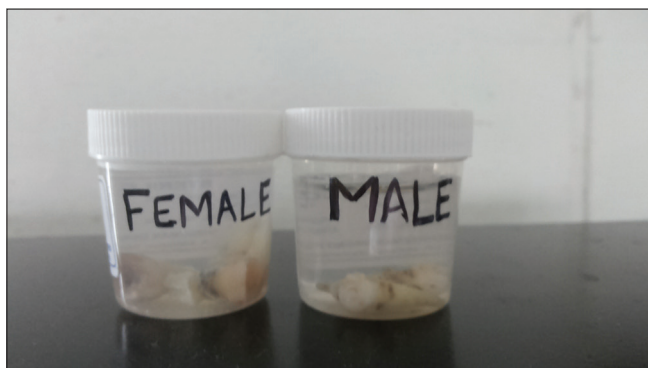## Materials and Methodology

The study sample consisted of sixty extracted teeth from thirty male and thirty female patients. Patients with sexual differentiation disorders (such as Turner's syndrome and Klinefelter syndrome) were not considered. Impacted teeth, teeth extracted for orthodontic purposes, and mobile teeth were included in the study sample, whereas nonvital teeth and grossly decayed teeth were excluded. The teeth were collected from the Department of Oral and Maxillofacial Surgery.

The teeth were extracted using conventional extraction procedures. The teeth were then cleaned with sterile water to remove the blood and organic debris. The teeth were collected in separate formalin-filled containers for males and females at room temperatures [Figure 1].

The teeth were held in a crucible and heated in a time-temperature controlled electric furnace [Figure 2]. The teeth were heated at 100°C, 200°C, 300°C, 400°C, 500°C, 600°C, 800°C, and 1000°C. The teeth (five male and five female) were placed for 5 min at each temperature. After they cooled to the room temperature, routine endodontic access opening was done to extirpate the pulpal tissue using endodontic broaches and files. This pulpal tissue was fixed in 10% formalin, processed and stained with hematoxylin and eosin stains.

Serial cut sections of 5 µm were observed under Olympus research microscope at ×40 magnification. The analysis procedure consisted of counting fifty cells per slide among which Barr body positive cells were counted.



**Figure 1:** Teeth were collected in separate formalin-filled containers for males and females



**Figure 2:** Teeth were held in a crucible and heated in a temperature controlled electric furnace

To consider a cell to be positive for Barr body, the cell should form a chromatin condensation in the periphery of the nucleus.

The number of Barr body positive cells were counted in all the slides and a descriptive analysis was made.

## Results

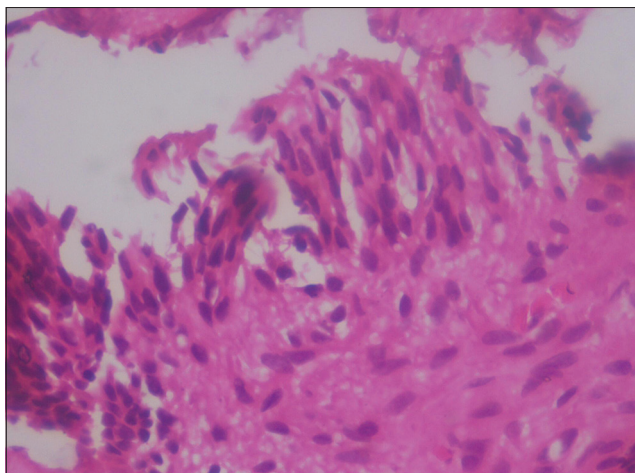
It was possible to extirpate pulpal tissue from teeth subjected to 100°C, 200°C, and 400°C. At higher temperatures, the teeth were burnt and charred and did not allow the extraction of pulpal tissue.

At 100°C, the morphology of the tooth did not change. Histologically, the male pulpal tissue showed diffusely arranged fibroblasts with hyperchromatic nuclei, but

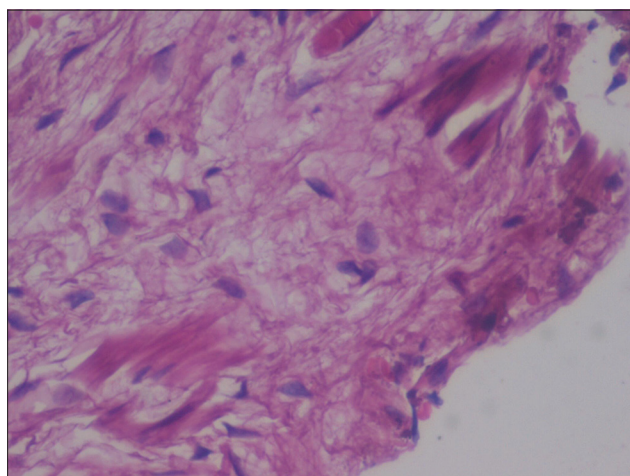
there was no evidence of any peripheral chromatin condensation representing Barr bodies [Figure 3]. In the females, the fibroblasts showed a basophilic hyperchromatic nucleus with a peripheral chromatic condensation of Barr chromatin [Figure 4]. An average of 19 Barr body positive cells was present per fifty cells from the female teeth that were heated to 100°C.

At 200°C, the external morphology of the teeth did not alter. The histological samples from the males showed low cellularity than observed at 100°C, with sparsely arranged collagen fibers and the fibroblasts lacked Barr chromatin.

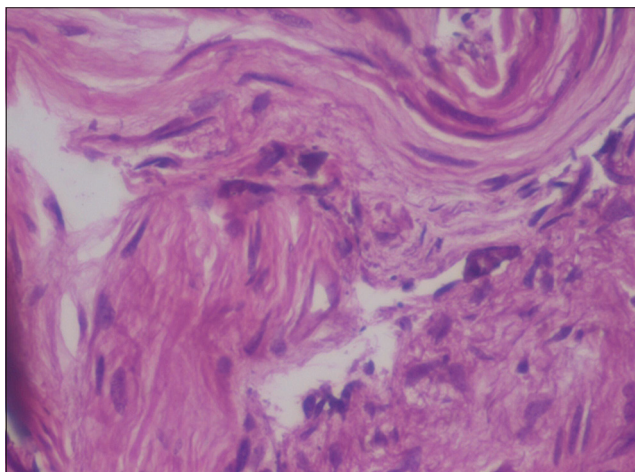
The females also showed hypocellularity with a sparsely arranged collagenous stroma. However, the fibroblasts did show the presence of peripheral Barr chromatin condensation [Figure 5]. In the female teeth that were heated



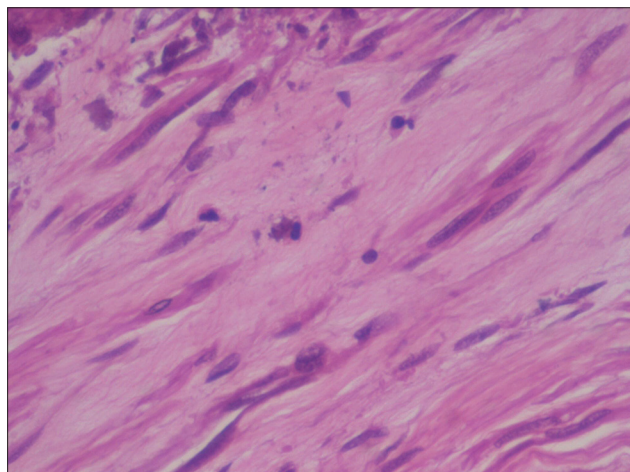
**Figure 3:** Male pulpal tissue at 100°C showed the presence of fibrovascular connective tissue. The fibroblasts lacked the presence of Barr chromatin



**Figure 4:** Female pulpal tissue at 100°C shows fibroblasts with prominent Barr chromatin condensation in the periphery of the nucleus



**Figure 5:** Female pulpal tissue at 200°C shows the presence of Barr chromatin in the fibroblasts. There is noted hypocellularity in the pulpal tissue



**Figure 6:** Female pulpal tissue at 400°C shows the presence of Barr chromatin in the nuclear periphery. Note the increased granularity of the nuclei



to 200°C, an average of twenty Barr body cells was seen in the fifty cells that were counted.

At 400°C, the root tips of the teeth showed brownish discoloration. The teeth were brittle and it were difficult to extract pulp. The amount of pulpal tissue that could be extirpated was also minimal. Histological analysis of male teeth showed disorganized collagenous matrix with hypocellularity. The few fibroblasts that were present lacked Barr chromatin condensation [Figure 6].

The female teeth, however, did show similar features such as hypocellularity and disorganized collagenous stroma, but the fibroblasts showed the presence of peripheral nuclear chromatin condensation. An average of 20 Barr body positive cells per fifty cells was present in the female teeth heated to 400°C.

A typical feature observed at 400°C is that the fibroblasts lacked the uniform basophilic nature of the nuclei and assumed a more granular appearance. This feature was seen both in the male and female samples.

Above 400°C when the teeth were heated, the teeth became calcified and very brittle. At 500°C, the teeth assumed a golden brown color; at 600°C, the roots were burnt; at 800°C, the entire tooth was burnt and the crowns broke away from the roots, whereas at 1000°C, the teeth became very fragile and charred like burnt coal. Therefore, above 400°C, the teeth were not suitable for further pulpal extraction.

## Discussion

Fire accidents are at an alarming rise. Burned human remains are a frequent site nowadays whether in fatal fires, terror attacks, or in public transportation mishaps. Fatal fire scenes provide some of the most difficult investigative challenges for fire responders, investigators, forensic experts, and law enforcement agents.<sup>[5]</sup> In some crime scenarios, forensic evidence is intentionally burnt to destroy the evidence and prevent identification. In such conditions, forensic identification becomes a tedious task and requires a great deal to expertise.

Even in such difficult situations when no other tissue is available or suitable for forensic identification teeth are preserved, as tooth enamel is the hardest structure in the body. Teeth, especially dental pulp is present in a casing of facial soft tissues, gingiva, maxillary or mandibular bone, enamel, and dentin. Thus, making it highly protected from the external fire stimulus in mishaps and making it available for further investigative procedures.

Sandholzer *et al.* classified six grades of fire injuries to teeth and jaws: (0) no injury, (1) injury to anterior teeth, (2) injury to anterior and posterior teeth (unilaterally), (3) injury to

anterior and posterior teeth (bilaterally), (4) fragments of jaw bone including teeth and/or roots, and (5) no dental remains.<sup>[6]</sup> Thus, teeth can be studied by their external morphology, polymerase chain reaction-DNA analysis studies, and electron microscopic studies. Pulpal tissue study is a more economical and easy way to study the features.

Therefore, in the present study, pulp tissue that has been extracted from teeth that have been subjected to an *in vitro* heat ranging from 100°C to 1000°C has been taken up and gender determination with the help of Barr chromatin was studied.

In our study, above 400°C, the teeth were brittle and were not efficient enough to be used as forensic evidence. The minimal tissue that could be extirpated also showed a highly disorganized pattern of connective tissue stroma and histological analysis was impossible. At 100°C, 200°C, and 400°C, the female cells showed fibroblasts with peripheral Barr chromatin condensation, whereas the males lacked Barr chromatin though they also showed a fibrovascular connective tissue stroma.

In females, at 100°C 38% (19 Barr body positive/fifty cells) positivity for Barr bodies was seen. At 200°C 40% (20 Barr body positive/fifty cells) and at 400°C 40% (20 Barr body positive/fifty cells), positivity could be seen. Therefore, in our study, with an increase in temperature, the average percentage of Barr body positive cells remained constant within a range of 38–40% (19–20 cells per fifty cells) which was in contrast to the studies conducted by Suazo *et al.*, who reported a 22% decrease in Barr body positive cells with increase in temperature.<sup>[7]</sup> Therefore, according to our study, an overall average of 40% of Barr body positive cells was in females within a temperature of 400°C.

With increasing temperatures, we also found hypocellularity of the connective tissue stroma in both the genders and teeth from all ages. A prominent finding at 400°C was the fibroblasts lost their uniform basophilic nature and assumed a more granular or vesicular appearance both in males and females.

Human body is exposed to fire during fire accidents, terrorist bomb explosions, plane crashes, etc. The temperature the bodies are exposed during a bomb explosion range from 260°C to 293°C,<sup>[8]</sup> whereas during a fire accident ranges up to 500°C. Oxygen is required for combustion. As already mentioned, dental pulp is present in a casing of dentin, enamel, alveolus, gingiva, and orofacial musculature. Thus, it is secured from the contact of oxygen during the fire accidents and therefore does not burn quickly until all the above structures are destroyed. Therefore, the teeth are preserved and the temperature that it comes into contact is also very less when compared to the external fire temperature.

## Conclusion

Therefore, pulpal tissue is a sustainable, easily available, conservable and inexpensive forensic identification tool, and can be used in gender identification procedures when no other sources are available. We would also like to mention that the heat exposure was done experimentally in an electric furnace and may vary slightly with the exact crime or mishap scenario. The study should also be tested under the effects of burial conditions, pH, salinity, and delay in processing.

## Acknowledgment

I would like to thank Dr. Bharathi.M, Prof. and HOD, Department of Prosthodontics and Dr.Chandrashekar.M, Prof. and HOD, Department of Conservative Dentistry and Endodontics for all their support during the course of the study.

## Financial support and sponsorship

Nil.

## Conflicts of interest

There are no conflicts of interest.

## References

1. Accidental Deaths and Suicides in India – 2013. NCRB- National Crime Records Bureau Ministry of Home Affairs, Government of India. Accident Statistics. Ch. 38. 2013.
2. International Committee of the Red Cross – Forensic Identification of Human Remains, [www.icrc.org](http://www.icrc.org), December 2013.
3. Zagga AD, Ismail SM, Ahmed H, Tadros AA. Forensic study for genetic sex determination of burnt powdered skeletal fragments from Sokoto, Northwestern Nigeria. *IOSR J Dent Med Sci* 2013;7:47-54.
4. Suazo GI, Roa HI, Cantín LM. Sex chromatin in dental pulp. Performance of diagnosis test and gold standard generation. *Int J Morphol* 2010;28:1093-6.
5. Symes SA, Dirkmaat DC, Ousley S, Chapman E, Cabo L. Recovery and Interpretation of Burned Human Remains. Final Technical Report Award 2008-DN-BX-K131.
6. Sandholzer MA, Baron K, Heimel P, Metscher BD. Volume analysis of heat-induced cracks in human molars: A preliminary study. *J Forensic Dent Sci* 2014;6:139-44.
7. Suazo GI, Flores A, Roa I, Cantín M, Zavando D. Sex determination by observation of Barr body in teeth subjected to high temperatures. *Int J Morphol* 2011;29:199-203.
8. Department of the Army Technical Manual – Military Explosive. Washington D.C.: Headquarters, U.S. Department of the Army; 25 September 1990.